

## KIDNEY FUNCTION AND STRUCTURE IN CHRONIC FLUOROSIS.

AUDREY M. BOND AND MARGARET M. MURRAY.

*From the Department of Physiology, Bedford College (University of London), London, N.W.1.*

Received for publication November 19, 1951.

CHRONIC fluorosis is known to occur in man as an endemic disease and also as an occupational disease in persons engaged in industrial undertakings where fluorine compounds, such as fluorspar ( $\text{CaF}_2$ ) or cryolite ( $\text{NaF} \cdot \text{AlF}_3$ ) are used as fluxes, or where materials are used which incidentally contain fluorine, as, for example, rock phosphates, certain phosphatic iron ores and even some coals. Persons residing in the vicinity of industrial undertakings which emit fluorine-containing gases, fumes or dusts are subjected to a fluorine hazard (Murray and Wilson, 1946).

Fluorine intoxication of a severe degree after prolonged exposure is readily diagnosed in man and animals by reason of the skeletal changes which result, but by the time these changes are demonstrable in man by X-ray studies, the functional disability may be considerable. It is proposed here to consider only the effects on the kidneys. In a survey of cryolite workers, Roholm (1937) concluded that it was doubtful whether renal lesions were typical of fluorine intoxication. He made post-mortem examinations of the kidneys in two workers; in one case he found proliferation of interstitial tissue, in the other case he found some stasis.

In studies on endemic fluorosis in man due to high fluorine content of the drinking water, attention has always been centred on the teeth and bone changes, but Linsman and McMurray (1943) reported a case in which they considered that renal impairment with retention of fluorine had been partly responsible for the osteosclerosis. Shortt, McRobert, Barnard and Nayar (1937) studied ten cases of endemic fluorosis and found in the majority impaired kidney function, but this might well have been due in part to other causes. The studies of McClure, Mitchell, Hamilton and Kinser (1945) have shown that in man a fluorine intake of 6 mg. per day can be eliminated completely by the kidneys, but that above this level there is retention; from then on the effects are cumulative. The use of fluorine in industrial processes has rocketed in recent years, and several outbreaks of animal fluorosis have been reported in Great Britain. Such outbreaks might also involve a hazard to the human population (Murray and Wilson, 1946).

Experimental animals, when fed small amounts of  $\text{NaF}$ , also exhibit bone changes, digestive disturbances, excessive water intake and polyuria (Roholm, 1937; Kick *et al.*, 1935). Post-mortem examination shows that the soft tissues also suffer changes.

An investigation has been carried out on the effects of the intake of small amounts of sodium fluoride on kidney structure and function in rats, with a

view to the possibility of establishing some means of testing for the toxic effects of fluorine in human beings, and of demonstrating the existence of a fluorine hazard before such severe intoxication has resulted as to cause disability and obvious skeletal lesions. The effects on kidney function are immediate.

#### METHODS.

Rats of an inbred hooded strain, kept at a controlled temperature of 68–70° F., were fed on a diet (Coward, 1938) consisting of maize meal 2600 g., wholemeal wheat 800 g., casein 360 g., dried yeast 200 g., NaCl 20 g., CaCO<sub>3</sub> 20 g., KI 1 g. *Addenda*: wheat germ 2 g., milk powder 5 g., cod liver oil 2 ml., green vegetables 2 g., liver or meat 2 g. The animals were put on the fluoride-containing diet at different times after weaning and received, according to age, 8 to 15 g. of the diet per day. The items of the addenda were each given once a week. In the control group the diet was mixed with tap-water and in the experimental group with 0.05 or 0.1 per cent sodium fluoride solution, using 1 ml. of either liquid to each gramme of diet. The amount of fluoride ingested, therefore, was from 4 to 15 mg./day. Different species of animals vary in their susceptibility to the effects of fluorine, and rats appear to be less readily affected than man, as judged by the effects on teeth. The animals were weighed weekly. Except where otherwise stated, all animals received tap-water *ad lib*. The volume drunk was measured daily, and at certain times the animals were transferred to metabolism cages so that the urine could be collected, measured and analysed. Blood samples were taken from the tail vein. Blood-sugar determinations were made on 0.05 ml., using a method described by King (1951). An endeavour was made to carry out renal clearances with inulin and *p*-amino hippuric acid, but the results on control rats were not consistent; hence these results were inconclusive.

#### RESULTS.

The results reported below have been gathered over some years, and are representative of observations made on a large number of control and experimental rats.

##### 1. *General observations.*

The intake of fluorine was sufficient to produce a state of chronic fluorosis. The animals developed definite symptoms, including the characteristic bleaching of the dental enamel with gross hypoplasia of the dental tissues and also bone changes, all of which have been fully described by previous authors (Roholm, 1937).

Investigations on fluorosis have been carried out in this laboratory for many years, and only very exceptionally have rats died during the fluoride administration at the relatively low level used, and then only after a year or more of exposure. The experimental rats showed retarded and diminished growth (see Fig. 1), which could in part have been due to the fact that at times, owing to the abnormal tooth development, the fluoride rats consumed less food than the controls. Most observers have attributed the diminished growth and loss of weight in adult animals to low food intake and to poor digestion and absorption, but our recent experiments have shown that in adult rats there is a much greater urinary excre-

tion of nitrogen. After several months on the diet there was a general loss of condition, and in some animals a staring coat. This could not have been due to deficiencies in the diet, but might have been due to a failure to absorb a sufficiency of essential nutrients (Spira, 1950). The fluoride rats ultimately showed greatly diminished body fat.

It was particularly noticeable that the fluoride-fed rats exhibited a much greater water intake as seen in Fig. 2(a) and (b); the effect came on immediately (see Fig. 2(b)), but was greater the longer the exposure to fluoride. Fig. 2(c) depicts the effect of administration of a natural water of high fluorine content (3 to 5 parts per million) which the animals had drunk, and which after con-

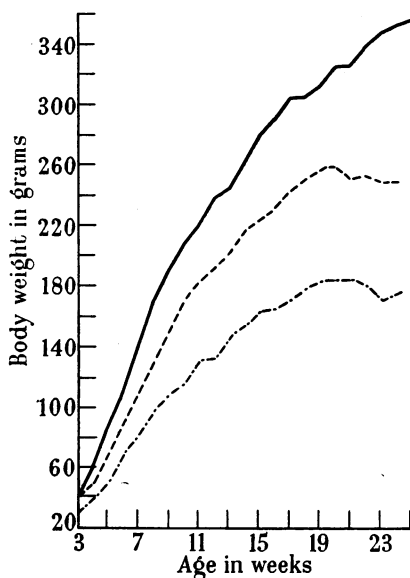


FIG. 1.—Growth rates of control and fluoride-fed male rats.

Control rats : —————  
 Diet mixed with 0.05 per cent NaF : - - - - -  
 Diet mixed with 0.1 per cent NaF : · - · - ·

centration to ten times its original strength and then equivalent to 0.008 per cent NaF was used for mixing the diet. In none of these experiments could the increased water intake and polyuria have been due merely to an increased salt intake, because a replacement of the NaF added to the diet by NaCl had no effect on the water intake. The effect was therefore judged to be due to the specific action of the fluoride ion.

The fluoride ion is well known to inhibit several enzyme systems (Borei, 1945), and noticeably those which are activated by magnesium. In some respects NaF acts, in the body as a whole, like KCN; animals injected with sub-lethal or lethal doses of NaF show marked cyanosis. This fact taken in conjunction with the increased water intake and polyuria led to a study of kidney function in the experimental rats.

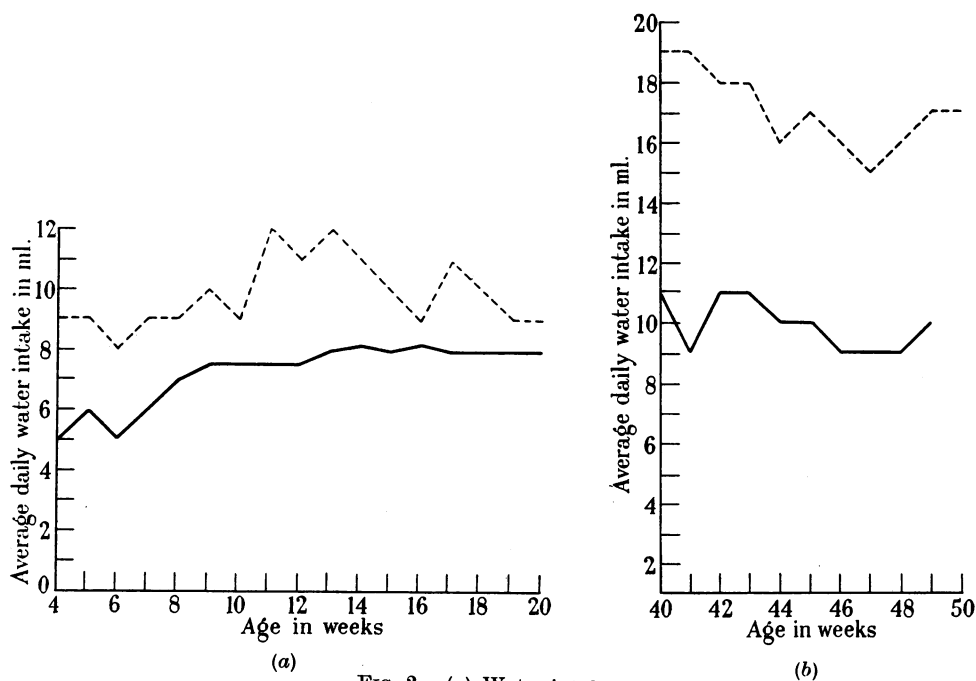
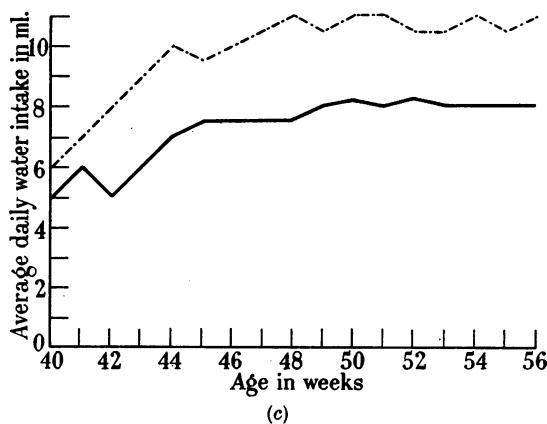


FIG. 2.—(a) Water intakes.

Water intake of control rats : —————  
 Water intake of fluoride-fed rats : - - - - -

(b) Water intakes.

Water intake of control rats : —————  
 Water intake of fluoride-fed rats after 40 weeks on diet : - - - - -



(c) Water intakes.

Water intake of control rats : —————  
 Water intake of rats drinking a natural water high in fluorine (3 to 5 p.p.m.) and receiving a diet mixed with this water concentrated 10 times and equivalent to 0.008 per cent NaF : - - - - -

Observations recorded when animals had been on diet 40 weeks.

At autopsy the kidneys of rats fed sodium fluoride for 10 months or more showed definite macroscopic changes; they were dark, shrunken and nodulated. A description of the histological findings in the kidneys is given below.

## 2. *Kidney function.*

Two groups of control and fluoride-fed rats kept in special metabolism cages were investigated. The rats of one group were 20 months old and had received the NaF for 10 months; the others were 6 months old and had been on the fluoride diet for 5 weeks.

The volumes of urine excreted by comparable groups of control and fluoride-fed rats can be compared from the figures given in Table II, which shows that there was a polyuria in the fluoride-fed rats. The average hourly volume of urine was 1 ml. for the fluorine rats and 0.25 ml. for the controls. The urine of the fluoride-fed rats was very pale and dilute and had a low specific gravity; it was free of albumin, blood pigments and casts. When food was withheld overnight, the urines of the fluoride-fed rats gave a positive test (Cole, 1944) for sugar at blood-sugar levels of between 70 and 80 mg./100 ml.

Both control and experimental rats were given a glucose tolerance test. Each rat was given 0.2 g. glucose/100 g. body weight injected intraperitoneally as a 5 per cent w/v solution in physiological saline. The controls showed a definite glycosuria, although the blood-sugar levels were never greater than 125 mg./100 ml. These results are given in Table I.

TABLE I.—*Sugar in Blood and Urine of Control and Treated Rats.*

|  | Control rats.  |     |    |   | NaF diet rats.                               |     |     |
|--|----------------|-----|----|---|--|-----|-----|
|  | Age 10 months. |     |    |   | Age 20 months.<br>(NaF given for 10 months.) |     |     |
| Fasting blood sugar (mg./100 ml.) .  | 70             | 80  | 67 | . | 80   | 66  | 70  |
| Sugar in "fasting urine" . . . .   | 0              | 0   | 0  | . | +  | +   | +   |
| Blood sugar (mg./100 ml.) 1 hour after<br>intraperitoneal injection of glucose . | 80             | 105 | 76 | . | 125  | 103 | 85  |
| Sugar in urine for 3-hour period after<br>glucose injection . . . . .            | 0              | 0   | 0  | . | +  | ++  | +++ |

It would therefore appear that the mild glycosuria of the fluoride rats was due to a lowered threshold rather than to diminished tolerance.

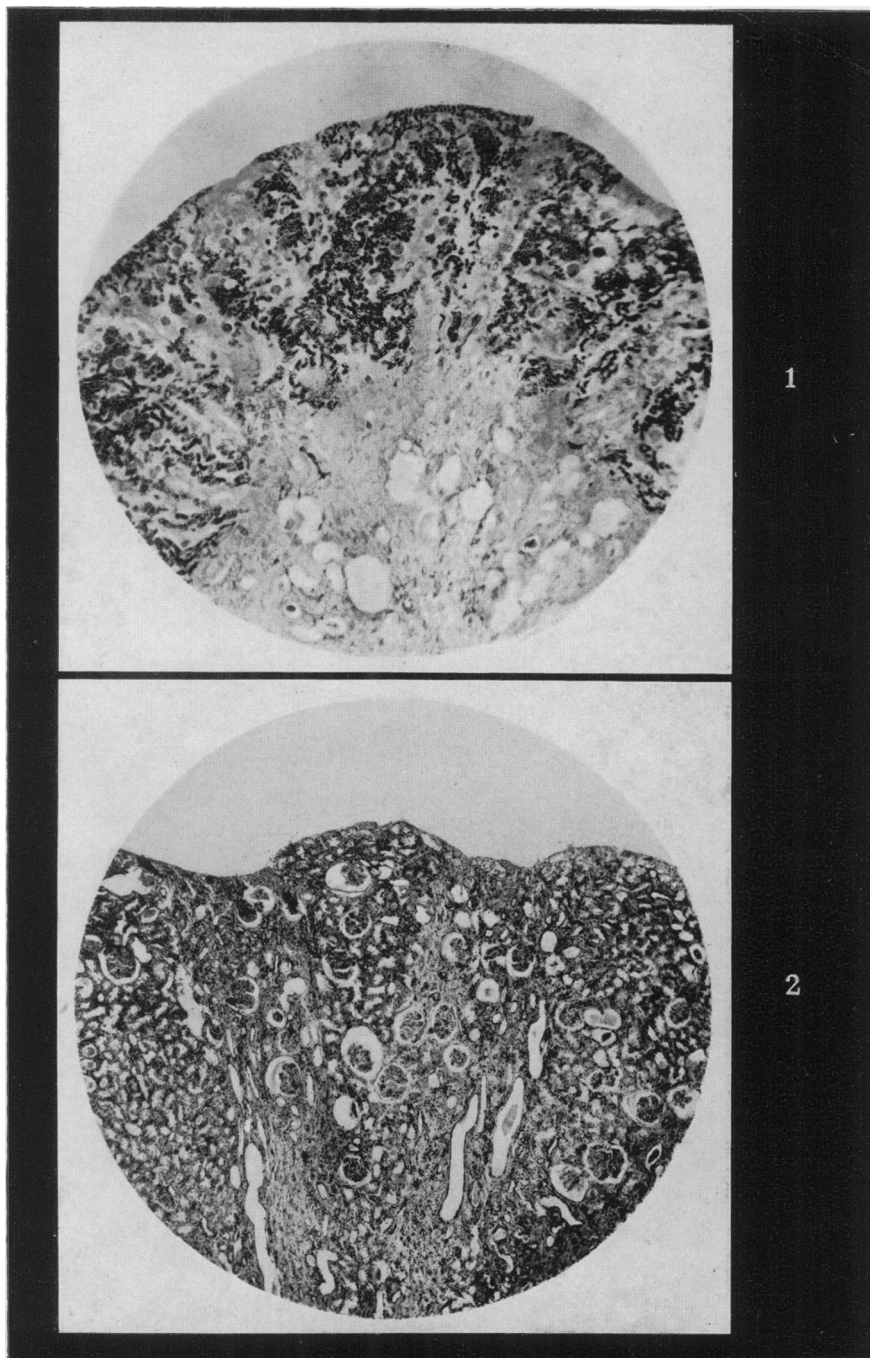
## DESCRIPTION OF PLATES.

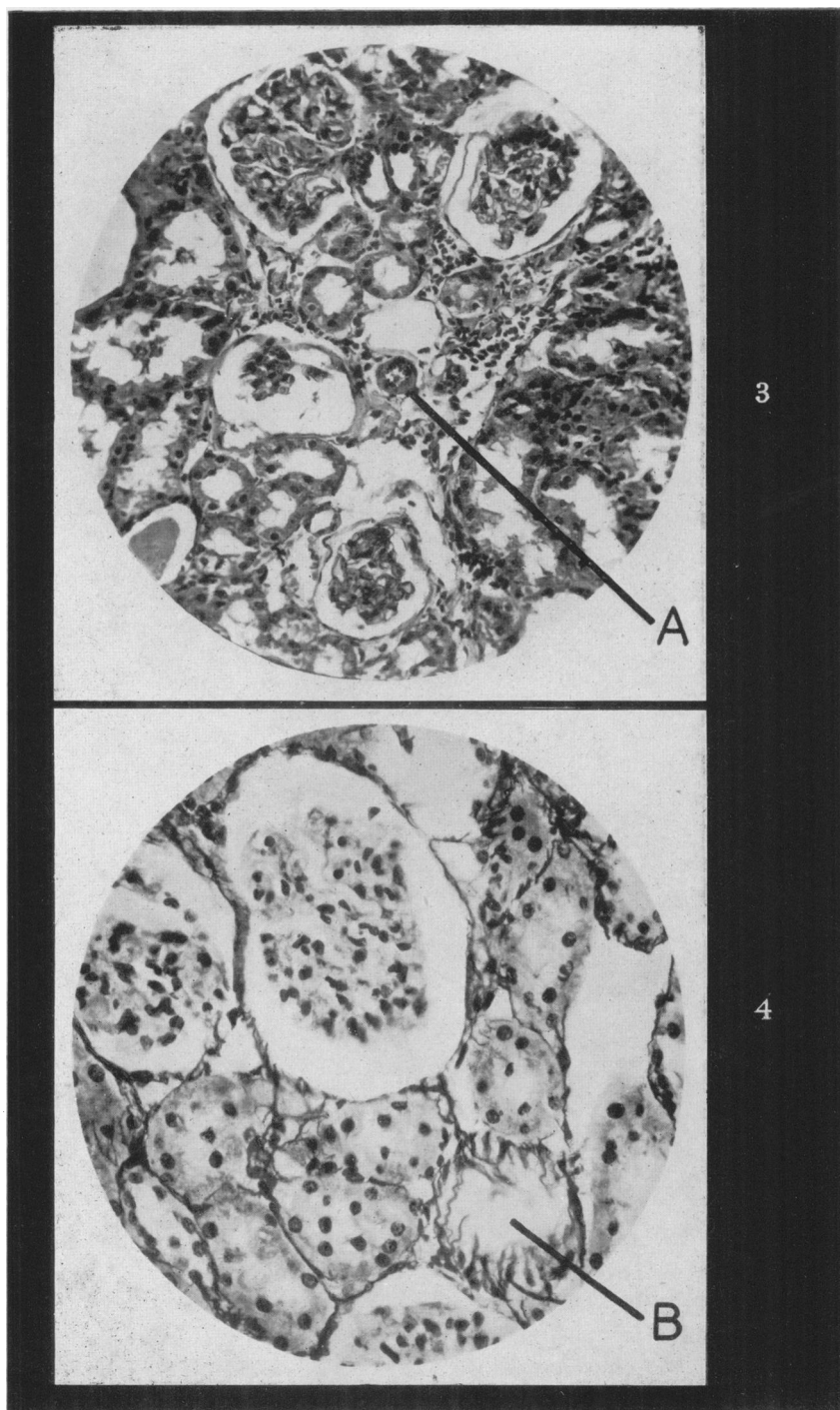
PLATE 1.—Photomicrograph  $\times 15$  of section of kidney of NaF-fed rat F23. Gomori's method for alkaline phosphatase; shows bands where the normal kidney tissue has been replaced by fibrotic tissue in which the phosphatase is absent.

PLATE 2.—Photomicrograph  $\times 38$  of section of kidney of NaF-fed rat F20. Haematoxylin and eosin; shows the fibrotic lesions giving rise to the mulberry-like appearance of the surface.

PLATE 3.—Photomicrograph  $\times 190$  of section of kidney of NaF-fed rat F20. Haematoxylin and eosin: shows at A arteriole with thickened walls. Changes in Malpighian corpuscles and convoluted tubules can also be seen.

PLATE 4.—Photomicrograph  $\times 315$  of section of kidney of NaF-fed rat F22. Silver impregnation for reticulin fibres; shows thickening and increase of these fibres; see B.





*Nitrogen metabolism.*—Emaciation is a marked feature of all farm animals suffering from chronic fluorosis, but this has usually been regarded as due to the difficulty in grazing, in eating or in rumination resulting from lameness in cattle or jaw deformity or abnormality of the dentition in sheep. The values we have obtained for urinary nitrogen excretion show that the emaciation could in part be due to an increased metabolism. Table II gives the results of urine analyses on rats kept in metabolism cages without food for 18 hours.

TABLE II.—*Characters of Urine in Control and Treated Rats*  
(18-hour collections).

|                                       | Control rats.  |        |       | NaF diet rats.                               |       |       |
|---------------------------------------|----------------|--------|-------|--|-------|-------|
|                                       | Age 10 months. |        |       | Age 20 months.<br>(NaF given for 10 months.) |       |       |
| Volume in ml. . . . .                 | 5              | 5      | 3     | 18   | 18.5  | 17.5  |
| Mean hourly volume in ml. . . . .     |                | (0.25) |       |  | (1.0) |       |
| pH . . . . .                          | 7.5            | 7.5    | 7.5   | 8  | 8     | 8     |
| Specific gravity . . . . .            | 1.026          | 1.026  | 1.026 | 1.011  | 1.010 | 1.014 |
| Total nitrogen (mg.) . . . . .        | 56             | 65     | 44    | 134  | 120   | 132   |
| Ammonia nitrogen (mg.) . . . . .      | 4              | 4      | 2     | 7  | 7     | 5     |
| Urea nitrogen (mg.) . . . . .         | 47             | 51     | 33    | 116  | 102   | 111   |
| Undetermined nitrogen (mg.) . . . . . | 5              | 10     | 9     | 11   | 11    | 16    |

### 3. *Alkaline phosphatase activity.*

Since it appeared that tubular function rather than that of the glomeruli was affected and because tubular function depends largely on enzymic activity, histological demonstration and chemical estimations of the level of alkaline phosphatase were made on both control and fluoride kidneys. In the latter the distribution of the alkaline phosphatase was very irregular (Plate 1); it was practically absent from the fibrotic pyramidal areas described in the histological report given below. In the other regions the phosphatase reaction was more intense than in sections of normal kidneys which had been similarly treated. Estimations of alkaline phosphatase in homogenates of the cortex of control and fluoride kidneys showed no consistent significant difference. This was at first surprising, but could probably be accounted for by the greater concentration in those regions of the fluoride kidneys where it was still present. This might be a response to the considerable loss of functional tubular tissue in the fluoride kidney. It may be mentioned here that in sections of the intestinal mucosa of the fluoride-fed rats we also found a patchy distribution, but in some places greater alkaline phosphatase activity, incubation for 5 min. giving as intense a test as 20 min. incubation of sections of normal intestine.

### 4. *Histological examination of kidneys.*

As a routine procedure whenever a fluoride rat was killed a control rat of the same age was sacrificed, and after post-mortem examination certain tissues and organs, including the kidneys, were taken for histological preparations. At least twelve fluoride and twenty control rats' kidneys have been given a general histological examination.

The sections described below were representative; the fibrotic changes seen in the fluoride kidneys varied in degree with length of exposure and from animal to animal, but in none of the control rats were these typical changes encountered.



It is our experience that in rats maintained on a good and varied diet as used in these experiments nephritis is not commonly seen, as it is in stock laboratory rabbits.

The following is a report on the histological examination of kidneys, by the late Dr. S. Roodhouse Gloyne:

Rats F20, F21 and F22 had been put on the NaF diet together at the age of 6 weeks. Rat F20 died, probably from another cause, aged 24 weeks. Its general condition was then poor, exhibiting a staring coat and marked dental fluorosis. The kidneys were dark, shrunken and nodulated. Rats F21 and F22, with rat A14, a control animal also aged 24 weeks, were sacrificed at the same time. Rat F23 was killed after receiving the NaF diet for 48 weeks. In appearance, including that of the kidneys, it resembled F20.

The kidneys of rat F23 were fixed in acetone for demonstration of alkaline phosphatase (Gomori, 1946) and those of the other rats in formalin saline. All sections were 5 $\mu$  in thickness. They were stained either with haematoxylin and eosin, or iron-haematoxylin and van Gieson's stain, or Mallory's connective-tissue stain, or by Foot's silver-impregnation technique for reticulin fibres.

*Microscopical examination.*—In all the kidneys examined the lesions were irregularly distributed. In the affected portions of the kidney tissue which corresponded with the areas devoid of alkaline phosphatase (see Plate 1) the following appearances were noted:

*Rat F20.—Malpighian corpuscles:* The basement membrane of Bowman's capsule was thickened and the capsular epithelium flattened and inconspicuous. The normal cleft-like or sickle-shaped subcapsular space was dilated. The glomerulus was contracted and markedly lobulated, the capillaries were thickened and in many instances difficult to define, but the nuclei of the visceral glomerular epithelium were generally demonstrable and erythrocytes were still present in considerable number (Plates 2 and 3). No leucocytic reaction was noted, and there were no haemorrhages.

*Convolutcd tubules:* The lumina of the convoluted tubules were often small. The cytoplasm of the cells lining these tubules was granular and here and there contained small vacuoles. The outlines of the cell envelopes were frequently difficult to define, the free borders were ragged and brush borders obliterated. Nuclei had disappeared in places, and there were tubules in which in cross-section all the cells seen were without nuclei (Plates 2 and 3). A few cystic dilatations of tubules occurred. The collecting tubules were also occasionally dilated and contained cellular debris.

*Arterioles:* In the neighbourhood of the glomeruli and along the collecting tubules arterioles exhibited considerable thickening of their walls as seen in Plate 3.

*Interstitial fibrosis:* Radiating outwards from the internal medullary zone to the cortex were elongated fibrotic strands of tissue (Plates 1 and 2), sometimes pyramidal in shape with their bases towards the cortex. These corresponded in position to the medullary rays of the normal organ, and they consisted of collecting tubules and arterioles irregularly compressed by collagen and reticulin fibres. Often all that was left of a tubule was an interrupted double row of nuclei of the epithelial lining. In other places the compression of the collagen fibres had resulted in cystic dilatations. Generally speaking the constricted arterioles and venules were found along the margins of the pyramidal strands.

The reticulin fibres were substantially thicker than those in a section of the kidney of the normal animal, and showed proliferation in some parts of the kidney. The region of the collecting tubules was most affected and there were dense ramifications of argyrophil fibres (Plate 4). Adjoining sclerosed glomeruli or atrophied tubules a thickened fibrous network was usually apparent.

*Rat F21.*—Microscopically the lesions noted resembled those seen in rat F20 but were on the whole rather more advanced. For instance, the cells of the convoluted tubules contained more fat droplets and had become more vacuolated and disorganised until in some areas nothing but a skeleton of cell envelopes lined the tubules. Here and there were collections of darkly-stained rounded or polygonal nuclei without cytoplasm surrounding the glomeruli and convoluted tubules. These appeared to be the remains of the epithelial lining of neighbouring convoluted tubules which had become collapsed, disorganised and obliterated. The collecting tubules tended to become more cystic in this animal. The pyramidal radiations of collagenous tissue were present as in rat F20.

*Rat F22.*—The kidney sections from this animal presented a picture which was in general similar to that of rat F20, but there was a greater proportion of normal tissue and the areas of the lesions were smaller.

The noteworthy features of the histological findings were :

- (1) The exudation of plasma into the subcapsular space of the Malpighian corpuscles and the contraction of the glomeruli.
- (2) Degeneration and collagenous thickening of arteriolar walls.
- (3) Progressive degeneration and disorganisation of the cell lining of the convoluted tubules.
- (4) Cystic dilatation of tubules.
- (5) The formation of pyramidal strands of collagen fibres containing constricted blood-vessels and compressed collecting tubules.
- (6) Coarsening of reticulin fibres.

These lesions suggest a chronic intoxication leading to a vascular, glomerular and tubular degeneration and finally an interstitial fibrosis. There is no evidence of an infective inflammatory lesion.

#### SUMMARY.

Rats given small amounts of NaF in the diet exhibited, in addition to the well-known skeletal and dental lesions, marked polydipsia and polyuria.

The urine of these rats was of low specific gravity, but free of albumin and casts.

There was slight glycosuria after 18 hours' fasting at blood-sugar levels of 70–80 mg./100 ml.

Administration of glucose intraperitoneally produced definite glycosuria at blood-sugar levels less than 125 mg./100 ml. Thus there was a low kidney threshold.

At autopsy the kidneys were dark, shrunken and nodulated.

Demonstration of alkaline phosphatase showed that there were fibrotic lesions in the cortex, where the enzyme was practically absent owing to absence of functional tubular tissue.

The histological examination indicated that in the kidneys there was a vascular,

glomerular and more obviously tubular degeneration leading finally to interstitial fibrosis.

The fluoride-fed rats showed diminished growth, and at low body weights there was a marked diminution of fat stores.

Nitrogen metabolism was greater in the fluoride-fed rats than in the controls.

This work has been financed in part by an expenses grant from the Medical Research Council, for which we wish to record thanks.

We should also like to thank Dr. D. C. Wilson for advice throughout the investigations.

#### REFERENCES.

- BOREI, H.—(1945) 'Inhibition of Cellular Oxidation by Fluoride.' Uppsala (Almqvist & Wiksiells).
- COLE, S. W.—(1944) 'Practical Physiological Chemistry.' Cambridge (Heffer).
- COWARD, K. H.—(1938) 'The Biological Standardisation of the Vitamins.' London (Baillière, Tindall & Cox).
- GOMORI, G.—(1946) *Amer. J. clin. Path.*, **16**, 347.
- KICK, C. H., BETHKE, R. M., EDINGTON, B. H., WILDER, O. H. M., RECORD, P. R., WILDER, W., HILL, T. J., AND CHASE, S. W.—(1935) 'Fluorine in Animal Nutrition.' *Bull. No. 558 Agricultural Experimental Station, Ohio*.
- KING, E. J.—(1951) 'Micro-Analysis in Medical Biochemistry.' London (Churchill).
- LINSMAN, J. F., AND McMURRAY, C. A.—(1943) *Radiology*, **40**, 474.
- McCLURE, F. J., MITCHELL, H. H., HAMILTON, T. S., AND KINSER, C. A.—(1945) *J. industr. Hyg.*, **27**, 159.
- MURRAY, M. M., AND WILSON, D. C.—(1946) *Lancet*, ii, 821.
- ROHOLM, K.—(1937) 'Fluorine Intoxication.' London (H. K. Lewis).
- SHORTT, H. E., McROBERT, G. R., BARNARD, T. W., AND NAYAR, A. S. M.—(1937) *Indian J. med. Res.*, **25**, 553.
- SPIRA, L.—(1950) *Exp. Med. Surg.*, **8**, 361.
-