

X-Ray Diagnosis of Fluorine-Associated Arthropathy

ZENG Guang-ling, Department of Radiology, Affiliated Hospital

I. Pathological basis and X-ray signs of fluorine-associated arthropathy

Long-term uptake of excessive fluorine may cause pathological changes of bone structure and bone periphery; furthermore, animal experiments and epidemiological investigations demonstrate that fluorosis may cause necrosis, degeneration and ulceration of articular cartilage, and also cause necrosis of subchondral bones, leading to hypertrophy of synovium and joint capsule and a series of reparative changes which will result in hyperostosis and hypertrophy of joint bones and subsequent joint deformity and dysfunction. These changes are called skeletal fluorosis-associated degenerative joint changes or skeletal fluorosis-associated arthropathy, and most people consider that the name of fluorine-associated arthropathy would be more definite and concise. This kind of arthropathy may be seen not only in the major joints of the appendicular skeleton of patients with skeletal fluorosis such as elbows, knees and hips, but also in small joints of the hands, feet and spine, especially in the wrist joints.

Since 1981, Beijing Jishuitan Hospital and Shanxi Academy of Traditional Chinese Medicine (TCM) have made successive observations on large pathological slices of dogs from regions affected by endemic fluorosis, and the results have been compared with X-ray and pathological results; in addition, the pathological changes in mice and rabbits with artificially-induced fluorosis have been investigated and other studies conducted to offer a scientific basis for understanding the pathology seen in X-rays of fluorine-associated arthropathy. In summary, this research has revealed the following seven pathological changes:

1. Necrosis of articular chondrocytes, degeneration and ulceration of matrix. X-rays could not reveal localized and superficial necrosis of cartilage. In case the entire cartilaginous layer was involved in the necrosis, the deep calcification belt and bone plate would be absorbed, thus X-rays would reveal localized indistinctness, damage and discontinuation of the osseous articular surface. At this time, most of the joint spaces did not show changes, or assumed localized stenosis, which is an early X-ray sign. (Figures 1 and 2)
2. Necrosis of articular cartilage, which may affect subchondral bones to cause osseous necrosis. After the dead bones have been cleared away by granulation tissue, X-rays may reveal local osteoporosis and cystic changes under the articular surface. There may be a single cyst or multiple cysts that mostly assume a round appearance, each about several millimeters in diameter. An individual region with cystic changes may reach 1–2 centimeters in diameter, and appears to be far away from the articular surface due to filming. When new bones formed around the region with cystic changes, a sclerotic ring would appear. (Figures 3 and 4)
3. In case the necrosis of articular cartilage was widespread, with degeneration and loss, X-rays would reveal stenosis of joint space. (Figure 5)
4. Pathological changes such as calcification in the deep layer of articular cartilage, deposition of many calcium balls, proliferation and thickening of cartilage, widening of calcification belts, subchondral hyperostosis and thickening of bone plates were reparative changes subsequent to cartilaginous necrosis. At this time, X-rays may show sclerotic and rough articular surfaces. (Figure 5) Sometimes, stripe-like or lamellar/punctate shadows of calcification or spinous calcification may appear between two osseous articular surfaces and connected with the articular surface, which should be attributed to calcification of articular cartilage. (Figure 4)
5. Proliferation of articular cartilage and continuous calcification to form bone, so that the bone end

became ossified in a stratified manner, bulged and deformed. The articular cartilage fused together with cartilaginous tissue from the synovial tissue to form cartilage bone, causing osseous protrusion at joint margins. X-rays would reveal hypertrophy, flattening or mushroom-like deformity in joint bone ends as well as bony spur hyperostosis at joint margins. (Figure 5)

6. Synovial tissue proliferated to form cartilaginous bodies connected to the synovium through their bases, and synovial blood vessels supplied nutrients to the cartilaginous bodies. After such cartilaginous bodies grew in size, their surface would be a cartilaginous membrane and their center would be chondrified bone, with the cartilage membrane separated from the bone by one annular calcification belt layer. X-rays would reveal bone masses in the joint capsule with rather high surface density, which is called a calcification ring. The center of the ring consisted of transparent cancellous bone with the bone trabecula structure visible. The larger bone masses were walnut-sized and affected the joint motions; these bone masses would become isolated bodies in the joints after their bases broke off. (Figures 6 and 7)

7. Hypertrophy and ossification of the ligaments, tendons and synovium around the joint was observed, manifesting as increased density of the joint capsule, with the joint capsule being indistinct, bulged, and assuming an arched calcification. The articular fossa may become deepened and enlarged. Spinous or zigzag protrusions appeared on the attaching site of tendons or ligaments on bones near the affected joint.

II. Establishment of the X-ray diagnosis of fluorine-associated arthropathy and X-ray grading

In fluorine-associated arthropathy, cartilage necrosis, necrosis of subchondral bones, and a series of reparative processes secondary to the necrosis are similar to the necrosis of articular cartilage and reparative changes of other diseases in terms of regularity. Since X-rays reveal common manifestations of degenerative osteoarthropathy, the X-ray diagnosis of fluorine-associated arthropathy must be established based on the following conditions:

1. Long-term residence in regions affected by fluorosis and with dental fluorosis (excluding those who migrated to regions affected by fluorosis after they had grown permanent teeth).
2. Existence of multiple populations with fluorine-associated arthropathy in the regions affected by fluorosis.
3. Involvement of multiple joints, and the disease breaks out on both sides and unevenly.
4. The bone structure of skeletal fluorosis and (or) peri-osseous X-ray changes are revealed concurrently.

We formulated the method for grading the X-ray findings of fluorine-associated arthropathy based on the pathological changes, the regularity of reparative processes, the clinical dysfunction of 287 cases with fluorine-associated elbow arthropathy in Enshi and the comparison with observations of X-ray grading. Fluorine-associated arthropathy is divided into 4 grades – early phase, mild, moderate and severe, in order to match the grading for skeletal fluorosis.

Early phase: Only slight changes of osseous articular surface occur; for example, localized indistinctness, absorption or discontinuation of articular surface, and at this time the joint space shows no changes. Most patients have no clinical dysfunction or have only early dysfunction (taking the elbow joint as an example, its extension and contraction is limited by 20° or so). (Figure 8)

Mild: Cystic changes occur under the articular cartilage, mild bony spur hyperostosis occurs, and the joint space may be normal or become widened or narrowed. Most patients have mild clinical dysfunction (extension and contraction is limited by 20°–40°). (Figure 9)

Moderate: The periphery of cystic changes in joints may be sclerotic; hyperostosis becomes noticeable; the joint space is narrowed; the articular surface becomes sclerotic and rough, and isolated bodies may be seen in the joints. All patients have clinical dysfunction above the moderate grade (extension and contraction is limited by at least 40°). (Figure 10)

Severe: The joint space becomes remarkably narrowed; osseous ends of joints are severely enlarged and deformed, and multiple isolated bodies of different sizes may be seen in the joints. All patients have serious clinical dysfunction (extension and contraction is limited by at least 60°). (Figures 10 and 11)

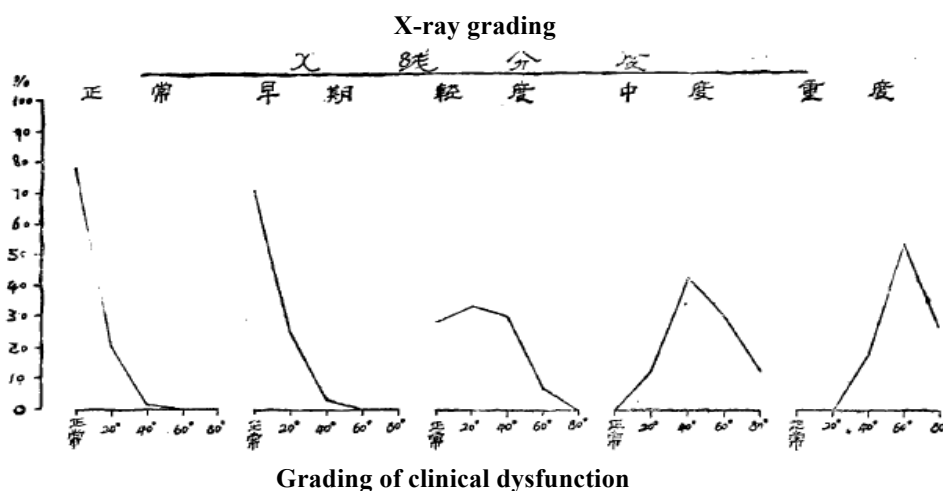
III. X-ray grading of fluorine-associated arthropathy and observations on the clinical joint dysfunction

The X-ray grading of fluorine-associated arthropathy has not been reported in prior literature. We proposed the four grades of X-ray findings for the first time at the national seminar of skeletal fluorosis held in Daxing County, Beijing in the autumn of 1982. In order to validate whether these grading criteria match the clinical findings, we made observations in the winter of 1982 on the clinical dysfunction of elbow joints and their X-ray grading in 287 cases with skeletal fluorosis from Enshi Prefecture, Hubei Province.

The clinical dysfunction was divided into the following 4 grades:

- Normal: The range of extension and contraction of elbow joint was over 140°
- Early phase: The range of extension and contraction of elbow joint was within 139°–120°
- Mild: The range of extension and contraction of elbow joint was within 119°–100°
- Moderate: The range of extension and contraction of elbow joint was within 99°–80°
- Severe: The range of extension and contraction of elbow joint was within 80°.

Two consecutive grades differed by 20°.



The X-ray findings were graded as follows pursuant to the criteria proposed at the Daxing seminar:

- Early phase: Only slight changes of osseous articular surface occurred.
- Mild: Cystic changes occurred under articular cartilage, and mild bony spur hyperostosis occurred.
- Moderate: Cystic changes and hyperostosis of joints became noticeable; the joint space was narrowed, and isolated bodies may be seen in the joint space.
- Severe: Joints were severely deformed, and multiple isolate bodies of different sizes may be seen in the joint space.

For each case, the range of extension and contraction of the right elbow joint was measured by a specially-made protractor to determine the clinical grading, and then the X-ray grading was determined based on the X-ray changes of the right elbow joint. Results are as shown in the following figure and table.

Comparative table between the clinical dysfunction and X-ray grading in 287 male cases with elbow arthropathy

Grading of clinical dysfunction	Total n %		X-ray grading									
			Normal		Early phase		Mild		Moderate		Severe	
			n	%	n	%	n	%	n	%	n	%
Normal: > 140°	115	40.1	79	78.2	20	71.4	16	28.6	0	0	0	0
Early phase: 139°-120° (20°)	56	19.5	21	20.8	7	25.0	19	33.9	9	13.0	0	0
Mild grade: 119°-100° (40°)	55	19.2	1	1.0	1	3.6	17	30.4	30	43.5	6	18.2
Moderate grade: 99°-80° (60°)	43	15.0	0	0	0	0	4	7.1	21	30.4	18	54.5
Severe grade: within 80°	18	6.3	0	0	0	0	0	0	9	13.0	9	27.3
Total	287	100	101	35.2	28	9.8	56	19.5	69	24.0	33	11.5

Note: (1) For grading of clinical dysfunction, two consecutive grades differed by 20° of limitation in extension and contraction of the elbow joint.

(2) X-ray grading was made pursuant to the criteria proposed at the Daxing seminar.

Based on the above figure and table, the following conclusions may be drawn:

1. Of patients showing early X-ray changes, most patients had no clinical dysfunction, accounting for 71.4%. A minority of them had early clinical dysfunction (range of motion limited by 20°).
2. Of patients showing mild X-ray changes, most patients had clinical dysfunction, accounting for 71.4%, that belonged to early and mild dysfunction (20°-40°).
3. All patients showing moderate X-ray changes had clinical dysfunction (100%); for most of them, the dysfunction was above the mild grade (over 40°), and for nearly half of them, the dysfunction was above the moderate grade (over 60°).
4. All patients showing severe X-ray changes had serious clinical dysfunction.
5. All patients having clinical dysfunction over 40° showed X-ray changes and all patients showing X-ray changes above the moderate grade had clinical dysfunction, demonstrating that the grading of clinical dysfunction agreed with the X-ray grading. For a few patients with early and mild changes, inconsistencies may occur because the pathological changes were mild and the individual tolerance was different.

To sum up the foregoing, the X-ray grading of fluorine-associated arthropathy basically agreed with the degree of clinical dysfunction. By adopting this X-ray grading method, the grading of X-ray findings of skeletal fluorosis will gradually tend to coincide with the grading of clinical manifestations of this disease.

Note: The third section of this article was written jointly with Sheng Ziqing from Enshi Municipal Hospital and Deng Kaifan from Enshi Medical Institute. The X-ray films were taken with the assistance of comrades from the Enshi Mufu Commune Health Center and the Dept. of Radiology, Jianshi County Hospital. We hereby express our thanks for their help.