

Complete oral rehabilitation in a case with severe dental fluorosis

Nikhil Joshi, Jayant Palaskar, Mahasweta Joshi, Rahul Kathariya

Nikhil Joshi, Jayant Palaskar, Department of Prosthodontics, Crown, Bridge and Implantology, Sinhgad Dental College and Hospital, STES campus, Vadgaon (Budruk), Pune 411041, Maharashtra, India

Mahasweta Joshi, Department of Public Health Dentistry, Sinhgad Dental College and Hospital, STES Campus, Vadgaon (Budruk), Pune 411041, Maharashtra, India

Rahul Kathariya, Dr. D.Y Patil Dental College and Hospital, Dr. D.Y Vidyapeeth (Deemed University), Pune 411018, Maharashtra, India

Author contributions: All the authors solely contributed to this paper.

Correspondence to: Dr. Rahul Kathariya, MDS, PhD, Dr. D.Y Patil Dental College and Hospital, Dr. D.Y Vidyapeeth (Deemed University), Pune 411018, Maharashtra,

India. rkathariya@gmail.com

Telephone: +91-89-83370741

Received: May 19, 2014 Revised: August 21, 2014

Accepted: September 23, 2014

Published online: December 16, 2014

plane

Core tip: A novel technique of full occlusal rehabilitation is illustrated here. It is a simple procedure which adheres to all the principles of occlusal rehabilitation. Rehabilitation of dental fluorosis using the treatment protocol suggested here will systematize and streamline the clinical technique and it is hoped that this approach will benefit the patients and act as a guide for dentists. Although the technique described here is skill sensitive, it is the author's belief that it is a new paradigm in full mouth occlusal rehabilitation.

Joshi N, Palaskar J, Joshi M, Kathariya R. Complete oral rehabilitation in a case with severe dental fluorosis. *World J Clin Cases* 2014; 2(12): 938-942 Available from: URL: <http://www.wjgnet.com/2307-8960/full/v2/i12/938.htm> DOI: <http://dx.doi.org/10.12998/wjcc.v2.i12.938>

Abstract

The authors have presented a technique of full occlusal rehabilitation in a case of severe dental fluorosis. In this technique, maxillary and mandibular anterior teeth were simultaneously prepared and restored first. This was followed by simultaneous preparation of maxillary and mandibular posterior teeth that were restored in canine guided occlusion. The technique and sequence followed here is unique and is not available in dental literature. This technique reduces number of appointments while fulfilling all objectives. Periodontal follow-up over 3 years was satisfactory. A restorative treatment protocol has been devised for fluorosis which will act as a guide for the dental practitioners.

© 2014 Baishideng Publishing Group Inc. All rights reserved.

Key words: Occlusal rehabilitation; Dental fluorosis; Treatment protocol; Restorative management; Occlusal

INTRODUCTION

There are hardly any documented cases in dental literature where dental fluorosis is treated by full occlusal rehabilitation. Restoration of dentitions affected by dental fluorosis is a challenging prospect. The presence of dental hypoplasia, the severity of discoloration, associated symptoms like hypersensitivity and attrition makes treatment planning extremely critical. The majority of fluorosis patients usually have mild to moderate fluorosis^[1,2] wherein the main symptoms are discoloration and/or very mild hypoplasia^[3,4]. These may be managed by simple restorative procedures like bleaching or composite filling. Some patients have moderate fluorosis which requires veneers or an occasional crown^[5-8]. Very rarely, patients with severe fluorosis require full occlusal rehabilitation. The protocol for treatment of dental fluorosis has been formulated in this article.

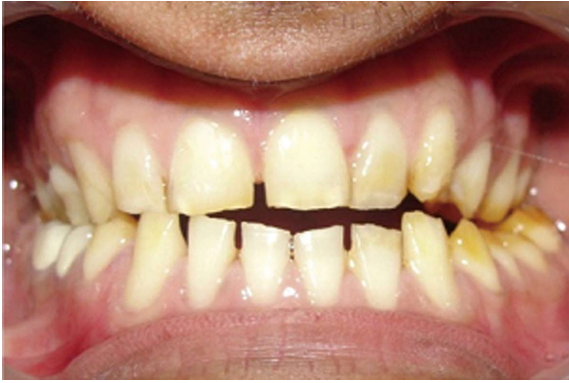

Figure 1 Baseline pre-treatment intraoral photograph.

This article documents a case of severe dental fluorosis with intraoral findings such as severe attrition, anterior open bite and unilateral cross bite, which was treated by full occlusal rehabilitation. Novel clinical and technical modifications were employed which may help to simplify the procedure of full occlusal rehabilitation.

CASE REPORT

A 28-year male patient reported to the Department of Prosthodontics, with a chief complaint of inability to chew food and discoloration of teeth. A detailed personal history revealed that the patient belonged to one of the fluoride belts of India. Clinical findings included protruded mandible, concave facial profile, severe dental fluorosis (Level 4 on Dean's Modified Index)^[9], maxillary midline not coinciding with mandibular midline, anterior open bite, unilateral crossbite with a few centric stops on left side, generalized severe attrition of teeth with moderate sensitivity (Figure 1). However, there was no loss of vertical dimension which could be attributed to passive eruption to compensate for the attrition. Diagnostic impressions were made using irreversible hydrocolloid (Zelgan 2002, Dentsply, India) and casts poured using dental stone (Kalabhai Karson Pvt. Ltd., India). Face bow (Hanau Springbow, Waterpik Technologies, United States) transfer was done and the casts were mounted using a centric relation record on a semi-adjustable articulator (Hanau H2, Whip Mix Corp, United States). All the clinical findings were confirmed by diagnostic mounting of the casts. Diagnostic wax up was done based on findings of clinical examination, diagnostic mounting and diagnostic wax up. Full occlusal rehabilitation using ceramometal crowns [Meta Cast (V), United States], without changing the vertical dimension at occlusion, was decided as the treatment of choice. The limitations of this treatment option viz., inability to coincide the maxillary and mandibular midline, inability to improve the facial profile and persistence of crossbite on left side were explained to the patient and his approval was obtained for the treatment plan. Maxillary and mandibular anterior teeth were prepared simultaneously to receive individual ceramometal crowns. Impressions were made using Vinyl Polysiloxane (GC America Inc, Made in Japan) by the putty-

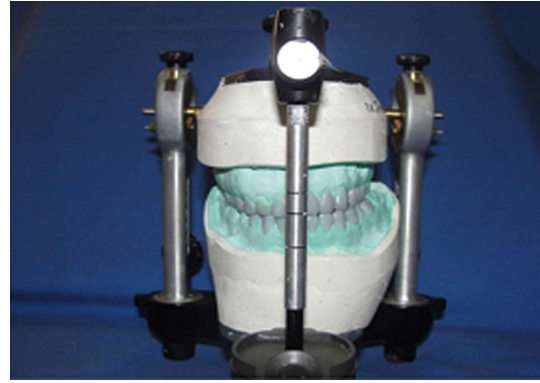


Figure 2 Centric relation and centric occlusion was verified in a semi-adjustable Hanau articulator.

wash technique^[10]. Individual temporary crowns (DPI, India) were fabricated using the indirect technique^[11] and were used to establish the anterior guidance in the patient's mouth in such a way that anterior temporaries provided canine guided occlusion. This was transferred to the semi-adjustable articulator and a custom incisal table was fabricated. The anterior metal try-in was carried out and ceramic (Vita VMK 95, Germany) build up was done according to the anterior guidance obtained from the patient. These definitive anterior restorations were seated in the patient's mouth, the canine guided occlusion verified and finally the anterior individual crowns were cemented using glass ionomer luting cement (Ketac Cem, 3M ESPE, Germany). The maxillary and mandibular midlines got close but could not be coincided. In the next phase of treatment, all the posterior teeth (maxillary and mandibular) were prepared simultaneously in a single appointment and a centric relation record was obtained. Impressions were made and master casts poured using die stone (Kalrock, Kalabhai Karson Pvt Ltd, India). The casts obtained were mounted on the semi-adjustable articulator. The horizontal and lateral condylar guidances were set arbitrarily at 20° and 15° respectively^[12]. The metal copings were fabricated and tried in the patient. Before the ceramic build up was started, the occlusal plane had to be established. This was set at the midpoint between the prepared maxillary and mandibular posterior teeth. After ceramic build up, the definitive restorations were tried in the patient, harmony of centric relation and centric occlusion was verified (Figure 2), canine guided occlusion was confirmed and the restorations were cemented.

Follow up

Follow up of the restorations and surrounding tissues was done for 3 years. Gingival and Periodontal component of Periodontal Disease Index (PDI)^[13] and Plaque component of PDI (Shick and Ash modification) was recorded at the beginning of treatment, every 3 mo for 1 year post treatment and every 6 mo for next 2 years (Figure 3). The Gingival and Periodontal component of PDI score before treatment was 2, in the first year post treatment it was 1 and for the next two years it was 0. Plaque

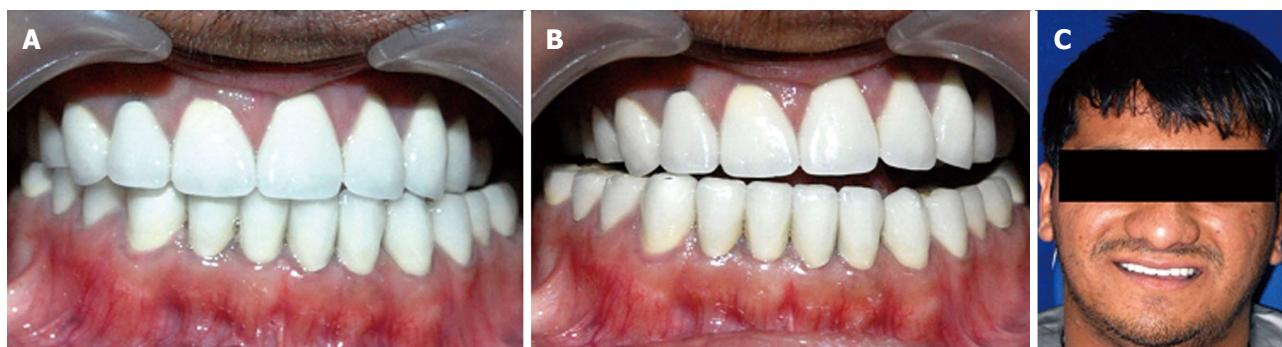


Figure 3 Follow up of the restorations and surrounding tissues. A: One year post-treatment intraoral photograph; B: Two year post-treatment intraoral photograph; C: Three years post-treatment extra oral photograph.

Modified dean's fluorosis index score	Clinical findings	Suggested treatment options
Normal (0)	Enamel represents usual transparency, semi-vitriform type of structure. The surface appears smooth, glossy and usually of a pale, creamy white colour	No treatment
Questionable (0.5)	Few flecks to occasional white spots	No treatment/bleaching
Very Mild (1)	Small, opaque, paper white areas scattered over < 25% of the tooth surface	No treatment /bleaching
Mild (2)	White opaque areas in enamel of the teeth are more extensive, but do not involve as much as 50% of the tooth	Bleaching/ composite restoration
Moderate (3)	All enamel surfaces of the teeth are affected and surfaces subject to attrition show wear. Brown stain is frequently a disfiguring feature	If discolorations accompanied by wear: Full coverage If only discoloration without any wear: 1 Bleaching or 2 Veneers (Direct or indirect) or 3 Bleaching followed by Veneers (Direct or indirect)
Severe (4)	All enamel surfaces affected, severe hypoplasia, discrete or confluent pitting. Brown stains are widespread and teeth often present a corroded-like appearance	Full coverage

component of PDI score before treatment was 2 and for the next three years it was 1. This indicated high compliance of oral hygiene instructions post-treatment by the patient and successful integration of the restorations in harmony with the periodontal apparatus. The patient expressed satisfaction with treatment and esthetics and restorations were sound and asymptomatic (no sensitivity to heat or cold, no pain/tenderness) at the follow-up visits. This three year follow up has reinforced that the treatment plan was sound and objectives of full occlusal rehabilitation were fulfilled while addressing all the pre-treatment problems of the patient.

DISCUSSION

Dental fluorosis is seldom so severe^[14-16] as to warrant full occlusal rehabilitation. In addition, complexities such as unilateral cross bite on left side, minimum occlusal contacts on right side, anterior open bite (as found in the present case) makes the prosthetic rehabilitation of such a patient challenging. Every attempt was made in this case to provide the best possible functional and aesthetic rehabilitation of the patient.

The dentition in full occlusal rehabilitation cases are restored variously following different principles and phi-

losophies. The canine guided occlusion is the favoured occlusal scheme, most often adopted in full occlusal rehabilitation^[17-24]. In this technique, the posterior teeth contact only in centric relation, the incisors are the only teeth contacting in protrusion and the canines are the only teeth contacting in mandibular lateral movements. In this patient, the canine guided occlusal scheme was implemented.

In canine guided occlusion the orientation and location of occlusal plane is not critical as long as it allows the anterior guidance to do its job. In this case, the occlusal plane was planned to be located midway between the prepared posterior teeth. This concept was relatively easy to apply as both the maxillary and mandibular posteriors were prepared at the same time and made the technician's job much easier. Since the technician received both maxillary and mandibular final casts with prepared posterior teeth, it was easier for her to establish proper contours and height of opposing restorations making optimum use of the available space. This technique is especially advantageous in cases of full occlusal rehabilitation restored using canine guided occlusion. In the present case, a technique has been attempted which simplifies the clinical and laboratory procedures of full occlusal rehabilitation while fulfilling all its objectives^[1,2,25].

The restorative procedures were divided into two components: anterior segment restoration followed by posterior segment restoration. The maxillary and mandibular anterior restorations were fabricated at the same time. Establishing the anterior guidance was also easier. Any adjustments and trimming could be done easily. When the posterior restorations were fabricated, developing the occlusal plane was greatly simplified as both the maxillary and mandibular segments were simultaneously prepared. The occlusal level was then set at the midpoint between the prepared maxillary and mandibular posterior teeth on the articulated casts.

Some occlusal rehabilitation philosophies recommend the restoration of posterior teeth prior to that of anterior teeth (*e.g.*, Hobo Twin-Stage procedure^[26]-Conditions 1 and 2). Other philosophies of full occlusal rehabilitation, including the Panky-Mann-Schuyler concept modified by Dawson^[12] recommend the sequential restoration of mandibular anterior segment, maxillary anterior segment, mandibular posterior and finally the maxillary posterior segment. The approach discussed in this article is unlike any other philosophies of full occlusal rehabilitation, is simple, requires least number of appointments, is unique and novel, and yet it fulfils all the requirements of full occlusal rehabilitation.

Hence clinical work is greatly simplified and patient appointments are limited to just 6 as follows: Appointment 1: Diagnostic impression, face bow transfer. Appointment 2: Preparation of maxillary and mandibular anterior teeth, impressions, temporization of anteriors. Appointment 3: Anterior metal try-in. Appointment 4: Cementation of anterior ceramometal crowns, selective grinding, finishing, polishing; preparation of all posterior teeth; impressions, face bow transfer, temporization of all posterior teeth. Appointment 5: Metal try-in of posterior restorations; Appointment 6: Cementation of posterior ceramometal crowns selective grinding, finishing, and polishing. Appointment 4 may be split into two depending on convenience of operator and/or patient.

Depending on the Modified Dean's Fluorosis Index^[9] which is the gold standard for quantifying dental fluorosis, a treatment protocol is herewith suggested (Table 1) which is meant as a guide; the operator may follow any treatment modality given in the protocol depending upon the skill-philosophy-convenience-preference.

The technique of full occlusal rehabilitation illustrated here simplifies the procedures while adhering to all its principles. Rehabilitation of dental fluorosis using the treatment protocol suggested here will systematize and streamline the clinical procedure and it is hoped that this approach will benefit the patient and act as a guideline for dentists.

COMMENTS

Case characteristics

This is a report of a case of severely discolored teeth, secondary to dental fluorosis; with generalized sensitivity, inability to chew food from both sides and deformed esthetics due to anterior open bite.

Clinical diagnosis

The patient had a concave facial profile with severe dental fluorosis (level 4 on Dean's Modified Index), with prognathic mandible, maxillary midline not coinciding with mandibular midline, anterior open bite, unilateral cross bite with a few centric stops on left side, and severe generalized attrition with moderate sensitivity.

Differential diagnosis

The differential diagnosis can be hypoplasia secondary to trauma to the teeth and jaws, any infections during pregnancy or infancy, poor pre-natal and post-natal nutrition, hypoxia, exposure to toxic chemicals and a variety of hereditary disorders, irregular vitamin D metabolism (vitamin D-resistant rickets) or chronic kidney failure at the time of tooth development.

Laboratory diagnosis

The tests included intra oral periapical and extra oral panoramic radiographs, diagnostic model mounting, pulp vitality testing of all teeth that confirmed the clinical findings of permanent hypoplastic teeth with sensitivity that were severely attrited and in malocclusion.

Imaging diagnosis

Imaging techniques used were orthopantomograph and intraoral periapical radiographs which showed generalized hypoplastic teeth, malocclusion, and anterior open bite.

Treatment

The treatment given was a full mouth rehabilitation using a specialized, simplified technique which is novel.

Term explanation

All terms are standard and established which have been used empirically.

Experiences and lessons

The approach to a full mouth rehabilitation case has to be holistic, patient specific and should fulfill all the criteria of scientific treatment protocol.

Peer review

This is an interesting and well written article. Methods are appropriate. Results are clearly presented. Discussion and Conclusions are really interesting.

REFERENCES

- 1 **Tabari ED**, Ellwood R, Rugg-Gunn AJ, Evans DJ, Davies RM. Dental fluorosis in permanent incisor teeth in relation to water fluoridation, social deprivation and toothpaste use in infancy. *Br Dent J* 2000; **189**: 216-220 [PMID: 11036750 DOI: 10.1038/sj.bdj.4800726]
- 2 **Catani DB**, Hugo FN, Cypriano S, Sousa Mda L, Cury JA. Relationship between fluoride levels in the public water supply and dental fluorosis. *Rev Saude Publica* 2007; **41**: 732-739 [PMID: 17923894 DOI: 10.1590/S0034-89102007000500007]
- 3 **Fluoridation facts**. Chicago (Illinois): American Dental Association, 2005:29. Available from: URL: http://www.ada.org/sections/newsAndEvents/pdfs/fluorodiation_facts.pdf
- 4 **Beltrán-Aguilar ED**, Barker LK, Canto MT, Dye BA, Gooch BF, Griffin SO, Hyman J, Jaramillo F, Kingman A, Nowjack-Raymer R, Selwitz RH, Wu T. Surveillance for dental caries, dental sealants, tooth retention, edentulism, and enamel fluorosis--United States, 1988-1994 and 1999-2002. *MMWR Surveill Summ* 2005; **54**: 1-43 [PMID: 16121123]
- 5 **Akpata ES**. Occurrence and management of dental fluorosis. *Int Dent J* 2001; **51**: 325-333 [PMID: 11697585 DOI: 10.1002/j.1875-595X.2001.tb00845.x]
- 6 **Bertassoni LE**, Martin JM, Torno V, Vieira S, Rached RN, Mazur RF. In-office dental bleaching and enamel micro-abrasion for fluorosis treatment. *J Clin Pediatr Dent* 2008; **32**: 185-187 [PMID: 18524266]
- 7 **Ardu S**, Stavridakis M, Krejci I. A minimally invasive treatment of severe dental fluorosis. *Quintessence Int* 2007; **38**: 455-458 [PMID: 17625627]
- 8 **Loyola-Rodriguez JP**, Pozos-Guillen Ade J, Hernandez-Hernandez F, Berumen-Maldonado R, Patiño-Marin N. Effectiveness of treatment with carbamide peroxide and hydrogen peroxide in subjects affected by dental fluorosis: a clinical trial. *J Clin Pediatr Dent* 2003; **28**: 63-67 [PMID: 14604145]
- 9 **World health organization**. Oral health surveys- basic meth-

- ods. 4^{ed}. Geneva: World Health Organization, 1997: 35-36
- 10 **Anusavice KL.** Phillips' science of dental materials, 11th ed. WB: Saunders Company, 2003
 - 11 **Rosenstiel SF,** Fujimoto J, Land MF. Contemporary Fixed Prosthodontics. 4th ed. St. Louis: Elsevier Health Sciences, 2006
 - 12 **Dawson PE.** Evaluation, diagnosis and treatment of occlusal problems. 2nd ed. CV: Mosby Company, 1989
 - 13 **Ramfjord SP.** The Periodontal Disease Index (PDI). *J Periodontol* 1967; **38**: Suppl: Suppl:602-610 [PMID: 5237683 DOI: 10.1902/jop.1967.38.6.602]
 - 14 **Clark DC.** Trends in prevalence of dental fluorosis in North America. *Community Dent Oral Epidemiol* 1994; **22**: 148-152 [PMID: 8070241 DOI: 10.1111/j.1600-0528.1994.tb01832.x]
 - 15 **Driscoll WS,** Horowitz HS, Meyers RJ, Heifetz SB, Kingman A, Zimmerman ER. Prevalence of dental caries and dental fluorosis in areas with negligible, optimal, and above-optimal fluoride concentrations in drinking water. *J Am Dent Assoc* 1986; **113**: 29-33 [PMID: 3461057]
 - 16 **Osuji OO,** Leake JL, Chipman ML, Nikiforuk G, Locker D, Levine N. Risk factors for dental fluorosis in a fluoridated community. *J Dent Res* 1988; **67**: 1488-1492 [PMID: 3198847 DOI: 10.1177/00220345880670120901]
 - 17 **Amico D.** Functional occlusion of the natural teeth in man. *J Prosthet Dent* 1961; **11**: 899-915 [DOI: 10.1016/0022-3913(61)90148-2]
 - 18 **Scaife RR.** Holt JE: Natural occurrence of cuspid guidance. *J Prosthet Dent* 1969; **22**: 225-229 [PMID: 5256070 DOI: 10.1016/0022-3913(69)90249-2]
 - 19 **Stuart CE.** Good occlusion for natural teeth. *J Prosthet Dent* 1964; **14**: 716-724 [DOI: 10.1016/0022-3913(64)90207-0]
 - 20 **McAdam DB.** Tooth loading and cuspal guidance in canine and group-function occlusions. *J Prosthet Dent* 1976; **35**: 283-290 [PMID: 1062598 DOI: 10.1016/0022-3913(76)90252-3]
 - 21 **DiPietro GJ.** A study of occlusion as related to the Frankfort-mandibular plane angle. *J Prosthet Dent* 1977; **38**: 452-458 [PMID: 269281 DOI: 10.1016/0022-3913(77)90100-7]
 - 22 **Goldstein GR.** The relationship of canine-protected occlusion to a periodontal index. *J Prosthet Dent* 1979; **41**: 277-283 [PMID: 283227 DOI: 10.1016/0022-3913(79)90007-6]
 - 23 **Siebert G.** Recent results concerning physiological tooth movement and anterior guidance. *J Oral Rehabil* 1981; **8**: 479-493 [PMID: 6947080 DOI: 10.1111/j.1365-2842.1981.tb00523.x]
 - 24 **Belser UC,** Hannam AG. The influence of altered working-side occlusal guidance on masticatory muscles and related jaw movement. *J Prosthet Dent* 1985; **53**: 406-413 [PMID: 3857338 DOI: 10.1016/0022-3913(85)90523-2]
 - 25 **Michael DW.** Failure in the Restored Dentition: Management and Treatment. Tokyo: Quintessence Publishing Company, 1995
 - 26 **Hobo S,** Takayama H. Oral rehabilitation clinical determination of occlusion, 1st ed. Tokyo: Quintessence Publishing Company, 1997

P- Reviewer: Boffano P, Gokul S **S- Editor:** Song XX
L- Editor: A **E- Editor:** Wu HL





Published by **Baishideng Publishing Group Inc**

8226 Regency Drive, Pleasanton, CA 94588, USA

Telephone: +1-925-223-8242

Fax: +1-925-223-8243

E-mail: bpgoffice@wjgnet.com

Help Desk: <http://www.wjgnet.com/esps/helpdesk.aspx>

<http://www.wjgnet.com>

