

---

## *Case Reports*

---

### Fluorosis - A Rare Complication of Diabetes Insipidus

**Meenakshi N. Mehta**  
**Kalyani Raghavan**  
**Varsha P. Gharpure**  
**Rajesh Shenoy**

The familial pituitary or central diabetes insipidus (DI) is a relatively rare condition with variable onset, from birth to several years of age and variable severity within a family and in individuals over time(1). Severe dehydration and growth retardation, though rare are known complications of DI. However, dental fluorosis as a complication of DI has been described in the literature only in three families(2,3). Further, severe crippling deformities due to skeletal fluorosis has not been reported in the literature to the best of our knowledge. We report two brothers with central diabetes insipidus who developed severe skeletal and dental fluorosis from early childhood.

#### **Case Report**

Two brothers aged 13 and 7 years, born of a non-consanguineous marriage, hailing from Bithuda village, District Pali,

*From the Division of Gastroenterology and Nutrition, Department of Pediatrics, Lokmanya Tilak Municipal Medical College and Lokmanya Tilak Municipal General Hospital, Sion, Mumbai 400 022.*

*Reprint requests: Dr. Meenakshi N. Mehta, 9, Shaivali, C/3, B.M.C. Colony, K.A.G. Khan Road, Worli, Mumbai 400 018.*

*Manuscript Received: February 13, 1997;*

*Initial review completed: March 11, 1997;*

*Revision Accepted: October 31, 1997*

Rajasthan presented with polyuria and polydipsia since infancy. Bony deformities and short stature were noticed in both since the time they began walking. The elder brother (MC) had persistent diarrhea in infancy and began to walk only after 3 years of age. The younger brother (JC), however, did not have diarrhea in infancy and started walking by 1 year of age. There was no history of similar complaints in other family members. On examination, the weight in both children were between 10th and 25th percentile of NCHS reference and height was less than 5th percentile. Both had a lordotic posture, anterior bowing of the humerus, bilateral bowing of the femur, knock-knees, saber shins, widening of the lower end of tibia and flat-feet (*Fig. 1*). The teeth were chalky-white with multiple pits (moderate as per Siddique's classification of dental fluorosis), more so in MC. The deep tendon reflexes were brisk in both the cases. Systemic examination did not reveal any specific abnormality. On detailed evaluation of parents, mother was found to have chalky white teeth with mottling and radiological evidence of fluorosis, but was clinically asymptomatic. Father, who was working in Bombay for many years, did not have evidence of fluorosis.

Investigations revealed normal hemogram, serum calcium (10 mg/dl each) and phosphorus (5.5 and 3 mg/dl, respectively). Alkaline phosphatase was elevated in both the cases [472 and 409 IU/L, Normal=21-91 IU/L]. The urine routine, liver function tests, renal function tests and arterial blood gas were normal. Skeletal survey revealed excessive bone density of all the bones, particularly the axial skeleton characteristically involving the spine, pelvis and the ribs. Increased trabecular conden-

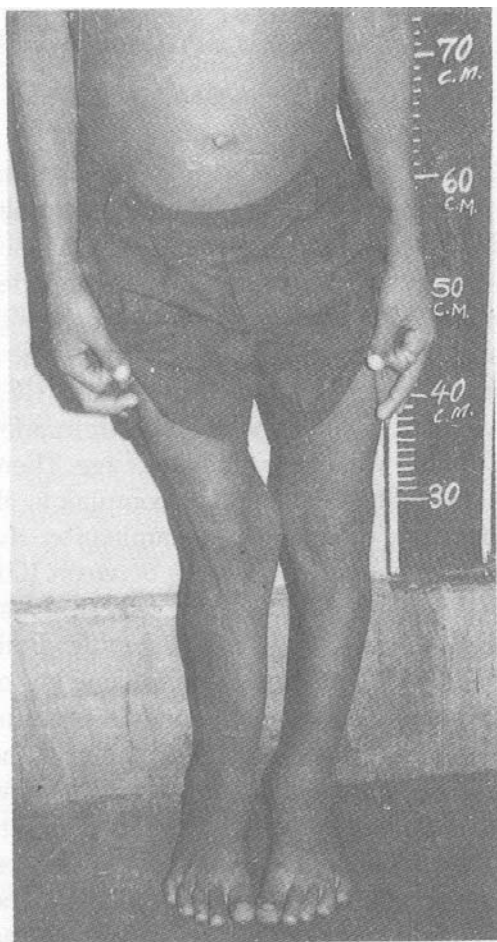


Fig. 1. Photograph showing bowing of femur and tibia, knock knees and saber shins.

sation created a radiodense or chalky appearance of thorax (Fig. 2). X-ray limbs also showed widened epiphyses, bowing of the femora, tibia and fibula. Orthopantomogram (dental X-ray) revealed root resorption of some teeth, periapical sclerosis and irregular dental roots (Fig. 3). CT scan of the brain in MC revealed bilateral basal ganglion calcification. However, there was no evidence of calcification in suprasellar region. Since these investigations were highly suggestive of fluorosis, the fluorine content of the well water in the village from where the children lived was asked for and was reported to be 3.4 ppm (Defence Laboratories, Jodhpur).

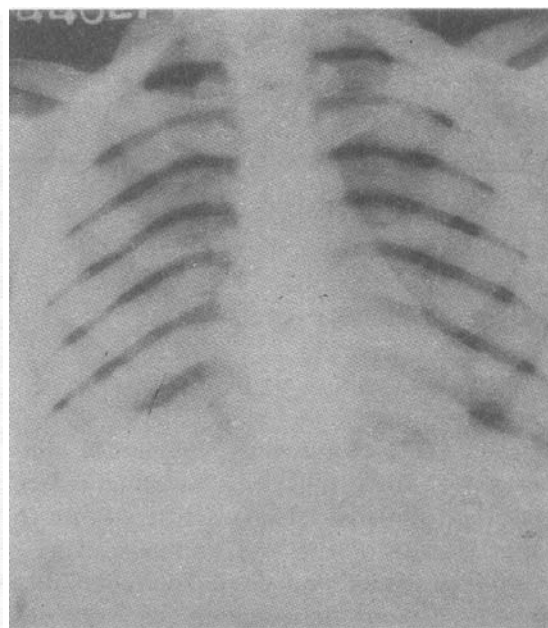
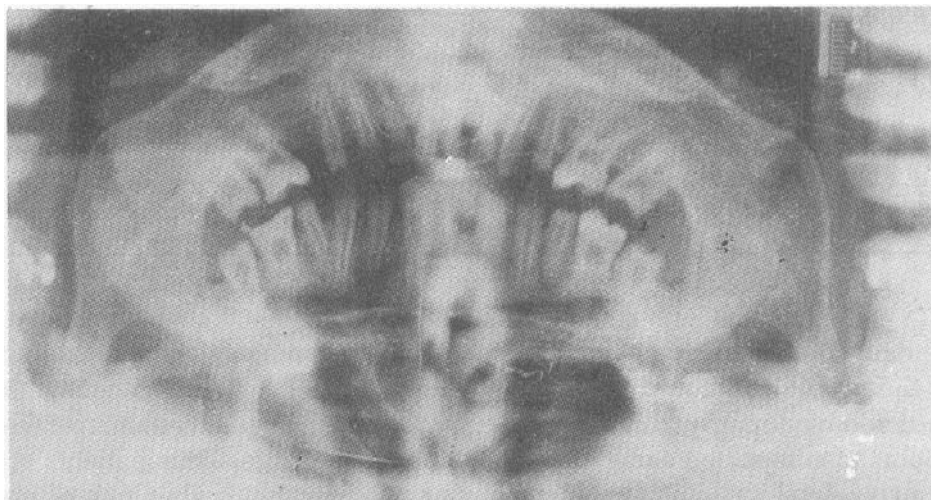


Fig. 2. X-ray chest showing thickened ribs with overall increased radio-opacity.

In view of polyuria and polydipsia patients were further investigated for diabetes insipidus. Specific gravity of urine after overnight water deprivation was 1.010. The maximal plasma (Posm) and urinary osmolality (Uosm) after water deprivation and after Injection Vasopressin (2. units SC) were recorded in both the brothers (Table I). More than 50% increase in maximum Uosm after vasopressin administration confirmed the diagnosis of central diabetes insipidus.

Since, polyuria was especially disturbing at night and in view of the high cost of therapy, both the brothers were advised Vasopressin as nasal spray (DDAVP, Minirin nasal spray - 10 µg/puff) at bedtime. While on this therapy, patients had marked relief from nocturnal diuresis. In addition to the above therapy, they were also advised regarding consumption of defluoridated water and were started on vitamin C at the time of discharge.



*Fig. 3. Orthopantomogram (dental X-ray) in which some teeth show root resorption, periapical sclerosis, irregular dental roots and enamel hypoplasia.*

### Discussion

Diabetes insipidus (DI), characterized by polyuria and polydipsia, results either from deficiency of antidiuretic hormone (central or pituitary DI) or from resistance of renal tubules to its action (nephrogenic DI). It is possible that DI may occur as a hereditary disorder, which can be either of central or of nephrogenic type(1). In the two sibs reported here, DI was of central type as proved from water deprivation studies and response to vasopressin. The diagnosis was further confirmed by relief of polyuria by vasopressin nasal spray. As two brothers from same family are affected, this DI seems to be of familial type, even though the exact mode of inheritance is difficult to ascertain as parents did not have DI. In the literature, autosomal dominant (AD) type of central diabetes insipidus has been documented(1).

Both the brothers in addition to DI had evidence of fluorosis, skeletal as well as dental. Fluorosis obviously developed from continuous and long term ingestion of drinking water from the village containing 3.4 ppm of fluoride. They showed the characteristic 'mottled enamel' involving the permanent as well as primary teeth

which is rare(4). The severity of mottling of enamel depends on the fluoride content of the drinking water, with levels above 2 ppm giving rise to mottling(4,5). The dental fluorosis in these patients appears to be of the 3rd or the severe grade by Siddique's classification commonly used by the Indian investigators(6). Dental fluorosis is an early evidence of fluorine induced damage and is present in people who are born and brought up in endemic areas(7).

In addition to the dental fluorosis, these brothers also had skeletal deformities and radiological evidence of skeletal fluorosis. Our patients showed almost dense opacity of all the bones, changes being most marked in ribs, long bones, pelvis. Interosseous membrane however, did not show calcification. Absence of 'bone on bone' appearance and other features like obtuse mandibular angle, persistent open anterior fontanelle and hypoplastic distal phalanges or the other typical features ruled out other conditions associated with increased bone density like Albert - Schonberg Disease, Pyknodysostosis, Dysosteosclerosis and Caffey's disease(1). Diagnosis of skeletal fluorosis was further strengthened due to associated classical

**TABLE I** *Summary of Tests*

Patient	Max Posm (mmol/kg)	Max Uosm (mmol/kg)	Uosm (Post Vasopressin) (mmol/kg)
MC	298	198	425
JC	310	138	280

changes of dental fluorosis. Brisk reflexes present in these children could be attributed to radiculomyelopathy due to cord compression as also reported earlier(8). Involvement of skeletal system is normally seen with fluorine content of water exceeding 8 ppm as per correlation of concentration of fluoride to the biological effects(5). The radiological changes are seen depending on the three stages in the evolution of skeletal fluorosis. In stage I, the spinal column and the pelvis show roughening and the blurring of trabeculae. In stage II, merging of the trabeculae leads to structureless appearance, bone contours become unclear, with changes most marked in the pelvis, spine and ribs. The medullary cavities may be narrowed and the ligaments may show early calcification. In stage III, the bones appear as marble white shadows especially in the axial skeleton. The cortex of long bones is thick and dense and the medullary cavity is reduced. The interosseous membrane may show calcification. It is surprising that our patients had crippling skeletal fluorosis even with water level of fluoride as low as 3.4 ppm. Two factors seem to be responsible for the development of severe fluorosis in our patients, the increased ingestion of water due to hot climate of Rajasthan, and the polydipsia due to the DI. So far in literature only 3 families have been reported with dental fluorosis and hereditary DI, one from Jerusalem(2) and the other 2 families from Australia(3). In the latter, the fluorosis developed in 2 children consuming optimally fluoridated

water (1 ppm) as against the remaining 4 members who did not consume fluoridated water and hence were spared from developing fluorosis. Thus patients with DI are at considerably higher risk of not only an early onset of fluorosis but also in more severe form. Relevant advice regarding consumption of safe water with safe fluoride content would prove useful in the management of subjects with DI.

#### Acknowledgements

We would like to thank the Dean, Lokmanya Tilak Municipal General Hospital and Lokmanya Tilak Municipal Medical College, Bombay for giving us permission to publish this article. We wish to give due credit to Dr. P.S. Menon and Dr. Nalini Shah from the Department of Endocrinology K.E.M. Hospital and Seth G.S. Medical College, Mumbai for the water deprivation test. We are also grateful to Dr. Ghosh from the Defence Laboratories, Jodhpur for providing the fluoride level concentration of the drinking water of the village.

#### REFERENCES

1. DiGeorge AM. Diabetes insipidus. *In*: Nelson's Textbook of Pediatrics, 15th edn. Eds. Behrman RE, Kliegman RM, Arvin AM. Bangalore, Prism Books Private Limited, 1996; pp 1574-1576.
2. Klein HDMD. Dental fluorosis associated with hereditary diabetes insipidus. *Oral Surgery* 1975; 40: 736-741.
3. Seow WK, Thompset MJ. Dental fluorosis

- as a complication of hereditary diabetes insipidus: Studies of six affected patients. *Pediatr Dentistry* 1994; 16:128-132.
4. Bhussey BR. Chronic toxic effects on enamel organ. *In: Flourides and Human Health*. Geneva, World Health Organization, Monograph Series No. 59, 1970; pp 230-238.
  5. Hodge HC, Smith FA, Gedalia JC. Excretion of fluorides. *In: Flourides and Human Health*. Geneva, World Health Organization Monograph Series No. 59, 1970; pp 141-162.
  6. Siddiqui AH. Fluorosis in Nalgonda district, Hyderabad-Deccan. *Brit Med J* 1955; 2:1408-1413.
  7. Jolly SS, Singh ID, Prasad S, Sharma R, Singh BM, Mathur OC. An epidemiological study on endemic fluorosis in Punjab. *Indian J Med Res* 1969; 57: 1333-1346.
  8. Singh A, Jolly SS. Endemic fluorosis with special reference to fluorine radioculomyopathy. *Quart J Med* 1961; 30: 357-372.

## Transplacental Aminophylline Toxicity

**Hemant S. Agarwal**  
**Ruchi N. Nanavati**  
**Manish S. Bhagwat**  
**Nandkishore S. Kabra**  
**Rekha H. Udani**

Asthma is a common disorder, with a prevalence of 4% in pregnant women(1) and 10% of them may have exacerbation during labor(2). Aminophylline is frequently used to relieve bronchospasm in

these women, but little is known about the placental transport and the effects on the fetus and the newborn. We report a case of transplacental aminophylline toxicity in this context.

### Case Report

A twenty-six-year old primigravida; a known case of bronchial asthma, developed an acute exacerbation at forty weeks of gestation. She did not respond to salbutamol and was admitted in a nursing home. She was treated with intravenous aminophylline (250 mg) and hydrocortisone without any improvement and was transferred to our institution. Here, she received two more doses of intravenous aminophylline (250 mg each); the last dose being two hours before delivery. A caesarean section was undertaken for persistent fetal tachycardia (180-190/minute) with poor beat-to-beat variability and non-progression of labor. She delivered a full term female neonate weighing 3150 g with Apgar scores of 3 and 5 at 1 and 5 minutes, respectively.

Within three minutes of birth, the neo-

*From the Department of Neonatology, Seth G.S. Medical College and K.E.M. Hospital, Parel, Mumbai 400 012.*

*Reprint requests: Dr. Ruchi N. Nanavati, 7 A, Suresh Colony, Near Nanavati Hospital, S.V. Road, Vile Park (W), Mumbai 400 056.*

*Manuscript Received: January 10, 1997;  
 Initial review completed: March 21, 1997;  
 Revision Accepted: October 28, 1997*