



Received on 09 November, 2017; received in revised form, 22 January, 2018; accepted, 06 February, 2018; published 01 August, 2018

QUERCETIN AMELIORATES OXIDATIVE STRESS, NEURAL DAMAGE OF BRAIN AND BEHAVIORAL IMPAIRMENT OF RAT WITH FLUORIDE EXPOSURE

Mesram Nageshwar, Kurmeti Sudhakar and Karnati Pratap Reddy *

Department of Zoology, Osmania University, Hyderabad - 500007, Telangana, India.

Keywords:

Behaviour,
Cerebral cortex, Hippocampus,
Oxidative stress, Quercetin

Correspondence to Author:

Prof. K. Pratap Reddy

Department of Zoology,
Osmania University,
Hyderabad - 500007,
Telangana, India.

E -mail: pratapkreddy@gmail.com

ABSTRACT: Excess fluoride causing fluorosis, can enter in to brain, disturb oxidative status and induce neural damage. Quercetin, antioxidant flavonoid stabilizes oxidative milieu of brain by quenching free radicals. The present study aimed to report ameliorative effect of quercetin on NaF induced oxidative stress, histological alterations in the brain and behavioural changes of rats. Rats were divided into four groups. The first group served as normal which received tap water. The second group was intoxicated with sodium fluoride (20 ppm/kg bw) through drinking water. The third group was given 20 ppm sodium fluoride in drinking water, along with treatment of quercetin (20 mg/kg bw) through oral gavage. The fourth group was treated with quercetin (20 mg/kg bw) through oral gavage. All animals were maintained for 60 days. Then, the antioxidant enzyme levels were measured, histopathological and behavioural studies were carried out. The results showed that the quercetin treatment significantly reversed the NaF induced increased lipid peroxidation (LPO) and decreased superoxide dismutase (SOD), catalase (CAT) and glutathione (GSH) levels in the brain homogenate. Quercetin also reversed the NaF induced Maze learning impairment, hot plate latency and histological alterations in cerebral cortex, hippocampal CA1 and CA2 regions in the brain. The study showed that the concomitant administration of quercetin protects rat brain from sodium fluoride induced oxidative stress, neural damage of brain and behavioural alterations.

INTRODUCTION: Flavonoids are polyphenol compounds present in plants and vegetables. Pharmacological studies show flavonoids play vital role in human health and have antioxidant properties including cardiovascular protection, cataract prevention and hepatoprotective as well as anticancer activities¹. Quercetin is a flavonoid present in plants including vegetables, fruits, red wine, barcoli, apples and onions²⁻³.

Quercetin is mainly responsible for the antioxidant activity of edible plants, which may protect against oxidative stress diseases such as diabetes, cancer and neurodegenerative disorders⁴. Nabavi *et al.*,⁵ reported that quercetin significantly attenuates oxidative damage induced by sodium fluoride by significantly restoring SOD and GSH levels and reducing LPO.

Several studies have reported quercetin is capable of crossing the blood brain barrier and reaching the central nervous system, essential for the treatment of neurodegenerative diseases⁶. Quercetin not only acts as an antioxidant with ability of direct hydrogen-donating properties to quench reactive oxygen species but also may exert modulatory actions on the endogenous antioxidative defense

<p>QUICK RESPONSE CODE</p> 	<p>DOI: 10.13040/IJPSR.0975-8232.9(8).3247-56</p> <hr/> <p>Article can be accessed online on: www.ijpsr.com</p> <hr/> <p>DOI link: http://dx.doi.org/10.13040/IJPSR.0975-8232.9(8).3247-56</p>
---	--

system by interactions with intracellular signaling cascades⁷. The anti-carcinogenic activity of quercetin inhibit cancer cell enhancement and modify the cellular signaling pathway in carcinogenesis and ameliorated the histological alteration in kidney and hepatic tissue⁸. Jiang *et al.*,⁹ stated quercetin treatment reduced histopathological damage in spinal cord injury.

Fluorosis is a one of the most complicated neurodegenerative diseases and it is a major problem in several countries in the world. Chronic administration of sodium fluoride induced neurodegeneration in central nervous system¹⁰⁻¹². Fluoride has capability to enter blood brain barrier and alter activity of free radical scavenging enzymes such as super oxide dismutase, lipid peroxidation and glutathione¹³. Free radicals play major role to damage biological systems in singlet oxygen species. Neural system is highly vulnerable to fluoride and it is observed that the fluoride accumulates in brain before skeletal system. Fluorosis alters the neuronal and cerebrovascular integrity resulting in cognitive and behavioral deficits in both humans and animals¹⁴. Several reports demonstrated neurodegeneration leads to cognitive impairment, motor coordination dysfunction, beta amyloid plaques formation and pathological abnormalities¹⁵⁻¹⁶. IQ scores of children living in endemic fluorosis area are less compared to children living in non-endemic area¹⁷⁻¹⁸. The severity of the adverse effects of sodium fluoride on the behaviour is directly correlated with the concentration of Fluoride ion in particular regions of the brain and in the plasma.

Furthermore, disturbances in brain development, longer latency of the pain reaction and conditioned reflex observed in rats at high concentration of Fluoride treatment¹⁹. The histological reports in rat exposed to fluoride seemed thickening and loss of dendrites, swelling of mitochondria, dilation of the endoplasmic reticulum in neurons and impaired hippocampus synaptic interface structure²⁰. Guan *et al.*,²¹ reported histopathological changes such as loss of purkinje cells, oligodendrocytes, demyelination in dendrites, mitochondria dysfunction, decreased Nissl granules in neurons of fluoride exposed animals. Recently we have reported that quercetin reversed monoamines epinephrine, nor-epinephrine and acetylcholine

levels in developing rat brain exposed to pre and post natal rats with NaF²². This study reports the neuroprotective effect of quercetin against sodium fluoride-induced oxidative stress, neuronal damage in the brain and behavioural changes in rat.

MATERIALS AND METHODS:

Chemicals: Quercetin, sodium fluoride, hematoxylin-eosin stain and congo red stain were purchased from sigma chemicals. All others chemicals were purchased from local firms for biochemical analysis.

Animals: The study was carried out on albino wistar rats (weighted about 250 - 300 g). Animals were housed in conventional condition at a temperature 24 ± 2 °C with a relative humidity of $60 \pm 5\%$ and a 12-h / 12-h light / dark cycle and maintained as per ethical committee guidelines. Animals were allowed in animal house one week before starting the experiment. The rats were divided randomly to four experimental groups of 10 animals each. The experimental period was 60 days. Group-I Control: these rats received only tap water. Group-II sodium fluoride: these rats received 20 ppm sodium fluoride through drinking water. Group-III Sodium fluoride + Quercetin: these rats received 20 ppm sodium fluoride through drinking water along with quercetin (20 mg/kg bw) through orally with gavage. Group-IV Quercetin: these rats received quercetin (20 mg/kg bw) through orally with gavage. The brain was dissected and stored at -20 °C for biochemical analysis, 10% formaldehyde used to store brain for histopathologicals studies.

Methods:

Biochemical analysis:

Lipid peroxidation (LPO): Lipid peroxidation in brain tissue was measured by modified method of Garcia *et al.*,²³. 1 mL of 10% homogenate was added to 1 mL of 20% TCA and heated at 70 °C for 10 min, and cooled at room temperature and centrifuged at 3000 rpm for 10 min. 400 μ L of supernatant was mixed with 200 μ L of 0.5% TBA reagent in a test tube covered with a glass marble and heated in a boiling water bath for 10 min and the tubes cooled to room temperature. The absorbance of the pink coloured trimethine condensation product was measured at 533 nm

using a spectrophotometer. The results were expressed as nano mole MDA/gm weight of tissue.

Superoxide Dismutase (SOD): Superoxide dismutase activity in brain tissue was estimated by modified protocol of Marklund and Marklund²⁴. The assay system in a final volume of 1.0 mL consisting 600 μ L of 83.3 mM Tris-HCl buffer, (pH 8.2), 100 μ L of 0.5 mM DETPA, 50 μ L of enzyme, 50 μ L of Tris-EDTA, 50 μ L of 0.01 N HCl, 100 μ L of H₂O₂ was mixed well and the reaction was initiated by adding the 50 μ L of 3.97 mM Pyrogallol. Increased absorbance was read at 420 nm using a spectrophotometer. The enzyme activity was expressed as Units/mg protein.

Catalase (CAT): Catalase activity was assayed following method of Aebi²⁵. A 10% tissue homogenate was prepared in 0.1M phosphate buffer (pH 7.4). Reaction mixture containing 200 μ L phosphate buffer (0.1M, pH 7.4) and 50 μ L of tissue extract, 250 μ L of 0.006M H₂O₂ was added and decreased in optical density was measured at 240 nm. One unit of activity is equal to the μ moles of degraded H₂O₂ /min/mg/ protein.

Glutathione (GSH): GSH was determined by the using method of Ellman²⁶. 1.0 ml of supernatant was treated with 0.5 ml of Ellman reagent and 0.3 ml of phosphate buffer (0.2 M, pH 8.0). The absorbance was read at 412 nm. The enzyme activity was expressed as μ g/mg protein.

Behavioural Studies:

Maze Learning Test: A maze is a puzzle in the form of a complex branching passage through which the starved animals try to find the food/goal. Maze test is the process of learning a route typically by rats through a maze in order to obtain reinforcement. This process is a popular experiment in behavioural laboratory and it is the main method of studying spatial learning. The rats were starved for 12 h before the maze learning experimentation. All experimental groups were trained two days before the experimentation, the animals were tested and the results were analyzed time in minutes²⁷.

Hot Plate Test: Hot plate test was performed according to the method²⁸. Rats were placed on the hot plate the temperature of floor consisting of a 52.5 ± 0.15 °C (Analgesiometer - Eddy's Hot Plat).

The response latency to either a hind-paw lick or a jump was recorded. In the absence of a response, animals were removed from the hot plate at 60 seconds (cut-off time) and 60 seconds latency was assigned as the passive response.

Histopathology: Brain sections were fixed in freshly prepared 10% formalin, processed routinely, and embedded in paraffin. Paraffin sections 5 μ m thick were prepared and stained with hematoxylin and eosin²⁹ and Congo red³⁰ for histopathological examination. Sections were examined using a light microscope (Magnification 40X).

Statistical Analyses: The results are expressed as the mean \pm standard error of the mean (SEM). Comparison of means were conducted using one way analysis of variance followed by least significant difference post hoc test to compare means between the different groups. Differences were considered as significant (P < 0.05). Statistical analyses were performed using SPSS version 20 software.

RESULTS:

Oxidative Stress Markers:

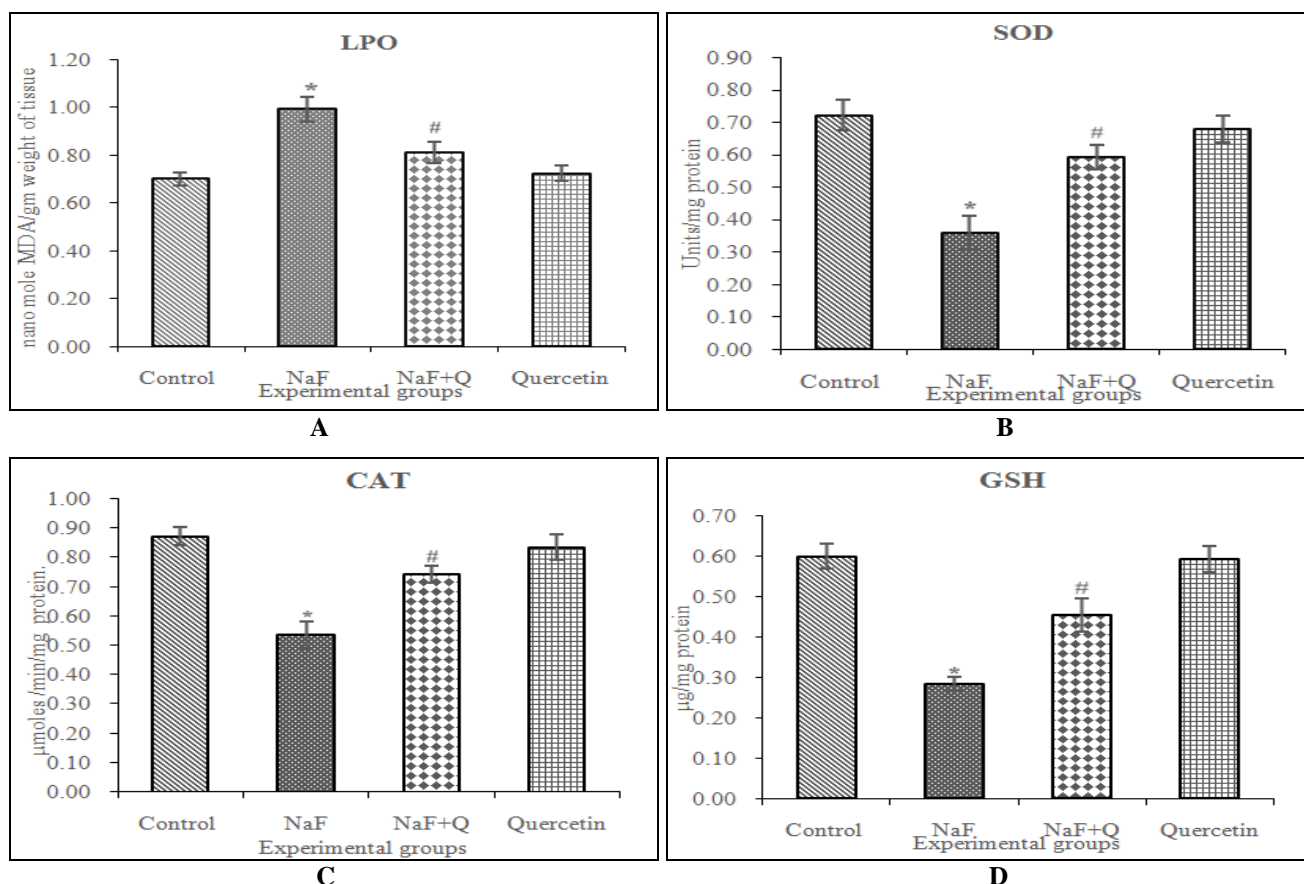
Effect on LPO Content, SOD, CAT and GSH Levels: As shown in **Graph 1**, brain LPO (**Graph 1a**) content was significantly increased (P < 0.05) in terms of MDA in NaF treated animals as compared with control group. It is significantly reduced (P < 0.05) in the NaF + Quercetin and Quercetin treated groups. The NaF treated group showed a significantly reduced (P < 0.05) levels of SOD (**Graph 1b**), CAT (**Graph 1c**) and GSH (**Graph 1d**) as compared with the control group, whereas their levels were significantly increased (P < 0.05) in NaF + Quercetin and Quercetin treated groups.

Behavioural Studies:

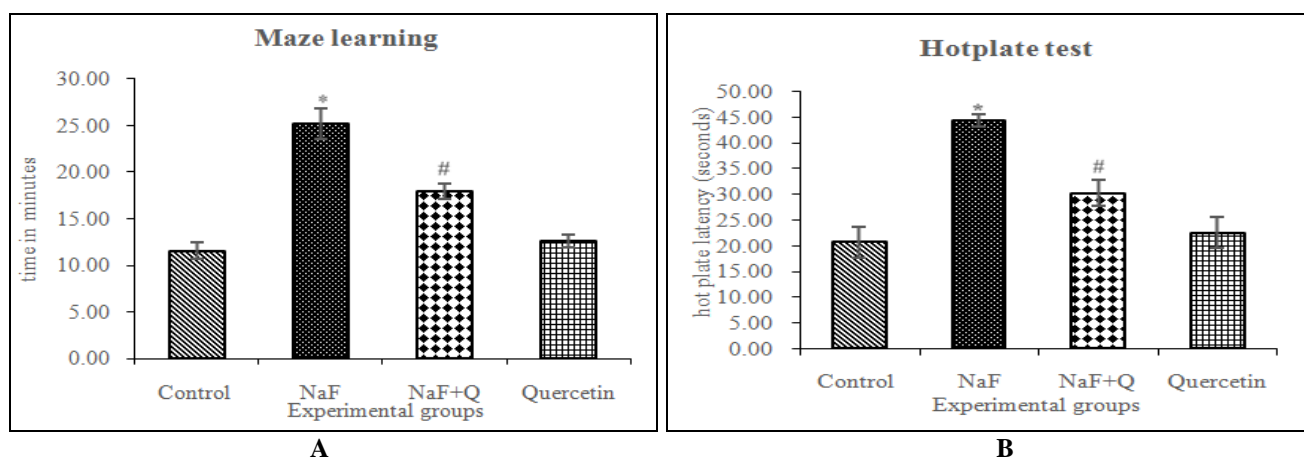
Maze Learning Test and Hotplate Test: As shown in **Graph 2**, spatial memory (**Graph 2a**) was assessed in terms of transfer latency on elevated plus maze. In the maze learning experiment the goal achieving time significantly (P < 0.05) increased was indicated in NaF treated group compared to that in the control group. Whereas NaF + Quercetin and Quercetin treatments significantly (P < 0.05) reduced the goal achieving

time compared to NaF intoxicated group. The paw withdrawal in hot plate test (**Graph 2b**) latency period significantly ($P < 0.05$) decreased in NaF exposure rats compared to control rats, and NaF +

Quercetin and Quercetin treated rats showed significantly ($P < 0.05$) increased the paw withdrawal latency period compared to NaF treated rats.



GRAPH 1: EFFECT OF QUERCETIN TREATMENT ON LPO (A) CONTENT, SOD (B), CAT (C) ACTIVITY AND GSH (D) LEVELS IN RATS SUBJECTED TO FLUORIDE TREATMENT FOR 60 DAYS. *P < 0.05 AS COMPARED TO CONTROL GROUP AND #P < 0.05 AS COMPARED TO FLUORIDE TREATED GROUP. DATA EXPRESSED AS THE MEAN ± S.E.M (n = 6) AND RESULTS EXPRESSED IN NANO mole mda/gm WEIGHT OF TISSUE (LPO), UNITS/MG PROTEIN (SOD), μ moles /min/mg PROTEIN (CAT) AND μg/mg PROTEIN (GSH)



GRAPH 2: EFFECT OF QUERCETIN TREATMENT ON COGNITIVE IMPAIRMENT (MAZE LEARNING TEST) AND LATENCY PERIOD (HOTPLATE TEST) IN RATS SUBJECTED TO FLUORIDE TREATMENT FOR 60 DAYS. *P < 0.05 AS COMPARED TO CONTROL GROUP AND #P < 0.05 AS COMPARED TO FLUORIDE TREATED GROUP. DATA EXPRESSED AS THE MEAN ± S.E.M (n = 6) AND RESULTS SHOWN IN TIME IN MINUTE AND SECONDS

Histopathology: Hematoxylin-eosin stain of cerebral cortex and hippocampus (CA1, CA2) regions of rat brain treated with sodium fluoride and quercetin are shown in Fig. 1 and 2. The shape of the cell, size of the cell, number of neurons and

nuclear membrane were markedly damaged in the cerebral cortex and CA1, CA2 hippocampus regions in NaF treated rat brain. This damage was markedly reversed up to normal in the NaF + Quercetin and Quercetin treated groups.

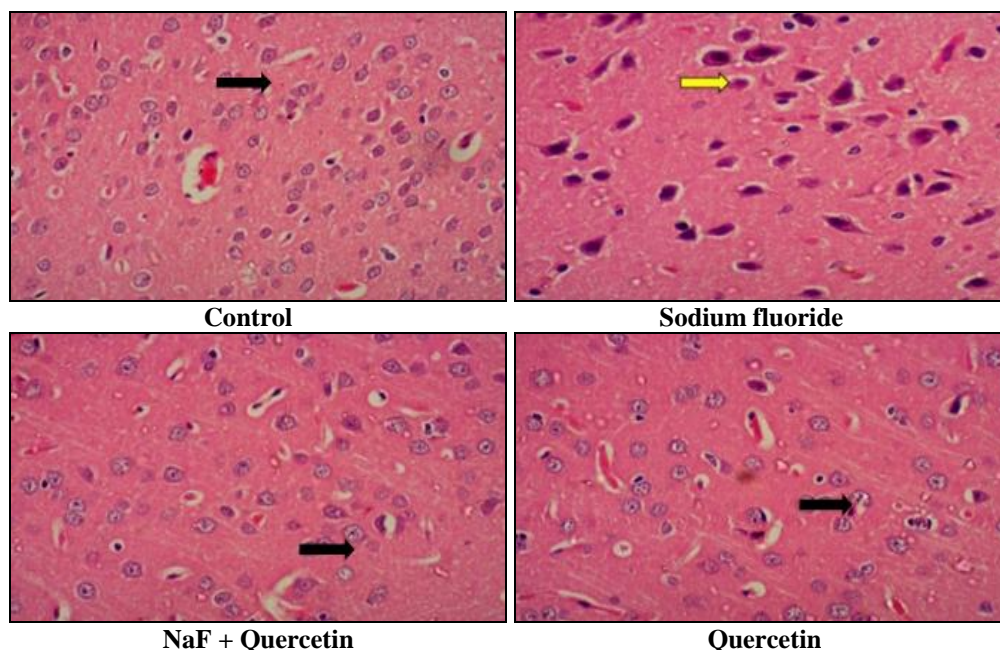


FIG. 1: MORPHOLOGICAL CHANGES IN THE CEREBRAL CORTEX REGION IN BRAIN (40X) (HEMATOXYLIN-EOSIN STAINING). THE CEREBRAL CORTEX IN THE CONTROL, SODIUM FLUORIDE, NaF + QUERCETIN AND QUERCETIN GROUPS, RESPECTIVELY. BLACK COLORED ARROW MARK SHOWING THE NORMAL CELLS WITH REGULAR SHAPE AND SIZE IN CONTROL, NaF + QUERCETIN AND QUERCETIN GROUPS AND YELLOW COLORED ARROW MARK SHOWING THE CELLS WITH IRREGULAR SHAPE AND NUCLEAR MEMBRANE WAS INDISTINCT IN THE NaF TREATED GROUP

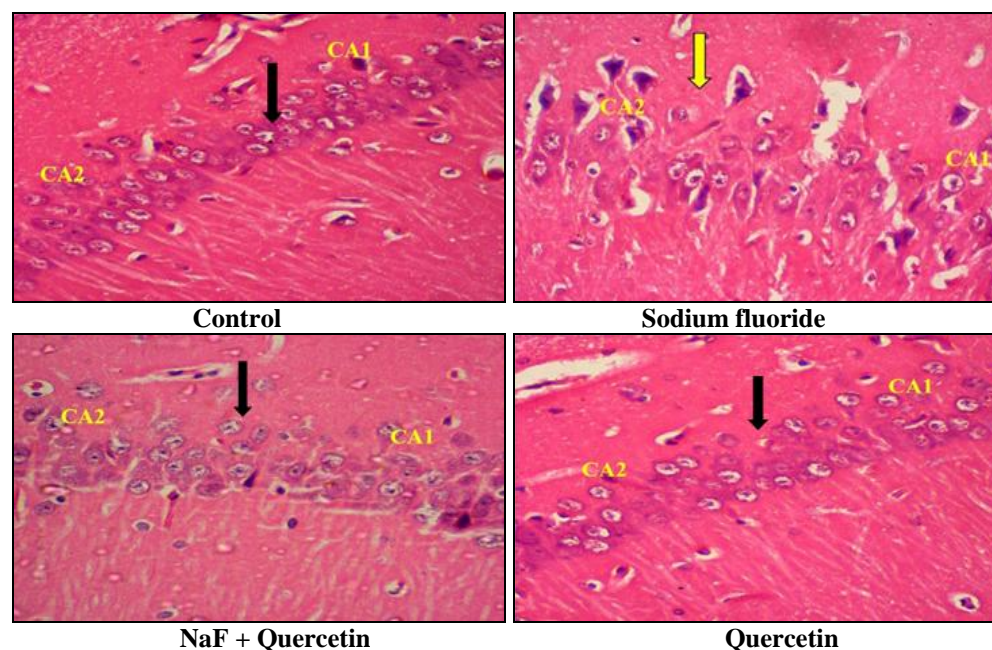


FIG. 2: MORPHOLOGICAL CHANGES IN THE HIPPOCAMPAL CA1, CA2 REGION IN BRAIN (40X) (HEMATOXYLINE-EOSIN STAINING). THE HIPPOCAMPUS IN THE CONTROL, SODIUM FLUORIDE, NaF + QUERCETIN AND QUERCETIN GROUPS, RESPECTIVELY. BLACK COLORED ARROW MARK SHOWING THE NORMAL CELLS WITH REGULAR SHAPE AND SIZE IN CONTROL, NaF + QUERCETIN AND QUERCETIN GROUPS AND YELLOW COLORED ARROW MARK SHOWING THE CELLS WITH IRREGULAR SHAPE AND NUCLEAR MEMBRANE WAS INDISTINCT IN THE NaF TREATED GROUP

The histological sections with congo red stain of cerebral cortex and hippocampal CA1, CA2 regions of rat brain treated with sodium fluoride and quercetin (Magnification 40X) are shown in **Fig. 3** and **4**. In congo red stain, amyloid plaque formation and irregular shape of neurons were

observed in NaF intoxicated rat cerebral cortex and CA1, CA2 hippocampus regions of the brain. The NaF + Quercetin and Quercetin treated groups were detected with decreased amyloid plaque formation and neuron regular shapes.

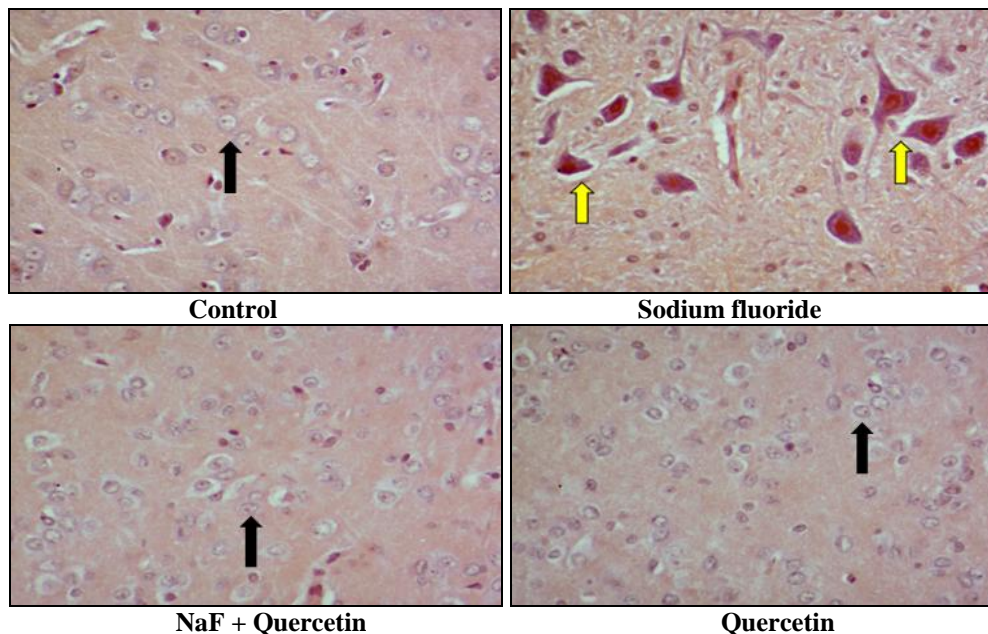


FIG. 3: BRAIN HISTOPATHOLOGICAL STUDIES IN CEREBRAL CORTEX BY CONGO RED STAIN IN CONTROL, NaF, NaF + QUERCETIN, QUERCETIN ALONE TREATED GROUPS. (MAGNIFICATION 40X). BLACK COLORED ARROW MARK SHOWING THE NEURONS ARRANGED CLOSELY, CIRCULAR SHAPE AND NUCLEAR MEMBRANE WAS CLEAR IN CONTROL, NaF + QUERCETIN AND QUERCETIN GROUPS AND YELLOW COLORED ARROW MARK SHOWING THE AMYLOID PROTEIN PLAQUES FORMATION, CELLS WITH IRREGULAR SHAPE AND NUCLEAR MEMBRANE WAS INDISTINCT IN THE NaF TREATED GROUP

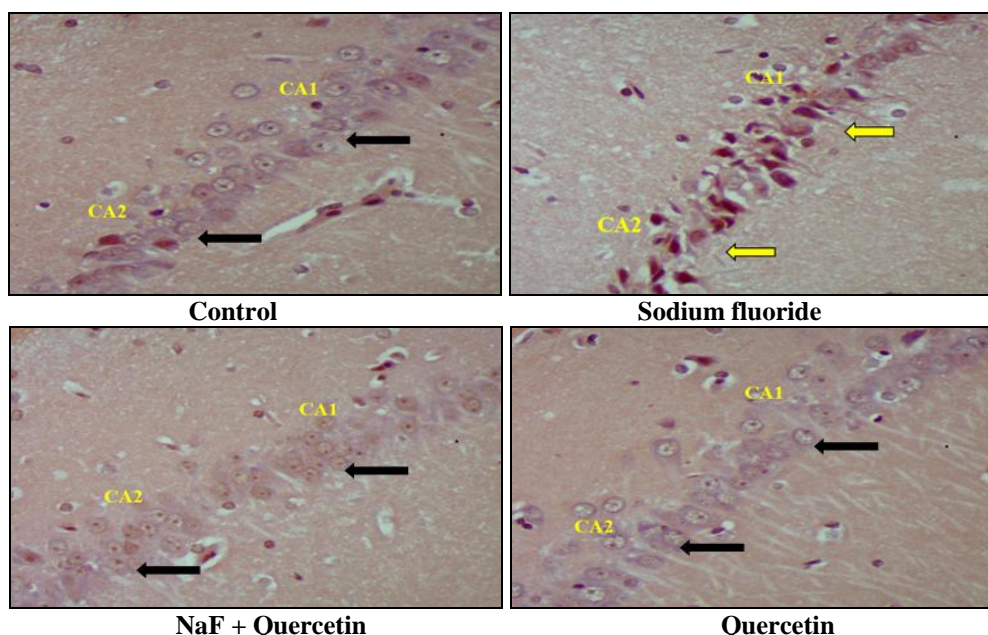


FIG. 4: BRAIN HISTOPATHOLOGICAL STUDIES IN HIPPOCAMPAL CA1 AND CA2 REGION BY CONGO RED STAIN IN CONTROL, NaF, NaF + QUERCETIN AND QUERCETIN ALONE TREATED GROUPS. (MAGNIFICATION 40X). BLACK COLORED ARROW MARK SHOWING THE NEURONS ARRANGED CLOSELY, CIRCULAR SHAPE AND NUCLEAR MEMBRANE WAS CLEAR IN THE HIPPOCAMPAL CA1 AND CA2 REGIONS OF CONTROL, NaF + QUERCETIN AND QUERCETIN GROUPS AND YELLOW COLORED ARROW MARK SHOWING THE AMYLOID PROTEIN PLAQUES FORMATION, CELLS WITH IRREGULAR SHAPE AND NUCLEAR MEMBRANE WAS INDISTINCT IN THE NaF TREATED GROUP

DISCUSSION: Sodium fluoride induced neurodegeneration is associated with the oxidative stress, histopathological and behavioural alterations in brain which is seen to be well ameliorated with the pretreatment with quercetin. This study provide evidences for the neuroprotective effect of the most abundant polyphenolic compound quercetin on sodium fluoride induced neurodegeneration in rat. It is observed that quercetin prevents sodium fluoride induced oxidative stress, behavioral and histopathological alteration in rat brain. Oxidative stress occurs when there is an imbalance between the reactive oxygen species production and the antioxidant defense systems and the production of ROS overcomes the antioxidant capacity of the cell. The central nervous system is vulnerable to oxidative stress. The brain utilizes great amounts of oxygen, consequently promoting the formation of oxygen free radicals and reactive oxygen species. Lipid peroxidation is considered as the main molecular mechanisms involved in the oxidative damage to cell structures and in the toxicity process that lead to cell death³¹. Lipid peroxidation was the consequence of toxic metabolites that produced highly reactive species, disruption of the intracellular membranes and cellular damage and it leads to neurodegeneration².

Some studies demonstrated significantly increased lipid peroxidation products MDA and 4-hydroxynonenal in the soft tissues intoxicated with sodium fluoride³². Superoxide dismutase is a master eukaryotic regulator of oxygen radicals, with cancer³³, cell biology and brain pathology³³. The antioxidant enzymes SOD and CAT play an important role in the enzymatic mechanisms. Superoxide dismutase converts the highly effective superoxide radicals into H₂O₂ (hydrogen peroxide). In the oxidative stress, catalase is responsible for the breakdown of hydrogen peroxide.

Therefore, the effects of the SOD and CAT are complementary to each other³⁴. Previous studies demonstrated superoxide dismutase activity decrease in sodium fluoride intoxicated rats liver and erythrocytes^{2,5}. Glutathione is a tripeptide an essential antioxidant, which is responsible for detoxification of hydroxyl and superoxide free radicals in the brain. In our lab also reported that the lipid peroxidation, superoxide dismutase, catalase and glutathione

levels were altered in sodium fluoride intoxicated rats³⁵. In the oxidative stress process glutathione is oxidized to make disulphide link to form oxidized glutathione. Catalase and Glutathione levels were depleted in sodium fluoride intoxicated rat liver, brain and kidney^{13,32}.

In the present study, we observed elevation in lipid peroxidation levels in the sodium fluoride intoxicated rat brain which is followed by a significantly decline superoxide dismutase, catalase and glutathione levels. The levels of brain lipid peroxidation were found to be restored in the rat treated with NaF + Quercetin and superoxide dismutase, catalase and glutathione levels were also restored. Quercetin provide to be significantly better in restoring the altered activity of antioxidant enzymes, superoxide dismutase, catalase, glutathione and lipid peroxidation towards their normal values in brain. This role of quercetin especially decreasing oxidative stress in brain by directly scavenging reactive oxygen species is further correlated with present results.

Another central effect that we highlighted was reversal of spatial learning ability of quercetin against sodium fluoride induced cognitive impairment. Our results have shown that sodium fluoride exposure caused an increase in goal reach time, as observed in the elevated puzzle maze task. The learning process is significantly restored in Quercetin treated groups. Normal learning ability was found in control and only quercetin treated rats. In fact, several studies have shown that fluoride exposure decreases cognitive process³⁶. High fluoride water supply affects the children's IQ as the fluoride affects structural damage to the central nervous system to such extent of functional impairment. Several studies indicated a lowering of IQ is associated with fluoride exposure³⁷. The mean IQ level of students exposed to high F drinking water was significantly lower than that of the students exposed to a lower F level drinking water³⁸. The present results indicated quercetin improves learning process of rats.

The hot plate evaluates central pain attenuation in a rodent using thermal stimulus known to be mediated through central processing pathways. The nociceptive pain in mice is triggered through the release of inflammatory mediators such sympatho-

mimetic amines, prostaglandins, and several cytokines, including IL-1, TNF- and IL-8 derived, from peritoneal macrophages and mast cells³⁹. The paw (plantar surface) withdrawal response on hot plate with constant temperature, thermal stimulus was measured as nociceptive response in quercetin and sodium fluoride treated rats. Present results were showed significantly decreased in thermal sensitivity response in sodium fluoride intoxicated rat where as the latency period reversed in quercetin treated groups and these results were similar to Gunn *et al.*,²⁸, Sudhakar *et al.*,³⁵.

In the present study, we observed marked morphological changes and β -amyloid plaques formation in the neurons of cerebral cortex and hippocampal CA1 and CA2 region of rat brain treated with Quercetin - NaF. The neurons had irregular shapes, shrunken and the nuclear membrane. The neurons were arranged closely, had a circular shape, nuclear membrane was clear in the control, NaF + Quercetin and Quercetin groups. The hippocampus and the cerebral cortex are the key structures of memory formation. Previous studies demonstrated that shrinkage in the pyramidal neurons, neuronal degeneration, and change in cell morphology have been reported in model of Alzheimer's disease⁴⁰⁻⁴¹.

Further investigation find β -amyloid plaques formation in the CA1 region⁴². Morphological analysis showed that the structure of neurons and mitochondria changed predominantly in the hippocampal CA3 region and cortex of AD model rats¹⁶. The fluoro-aluminium compounds produce neuronal injury in the CA1 and CA4 parts of the hippocampus of rat²⁰. The intracellular space, neutrophil infiltration and neuronal necrosis was observed in the hippocampus region in aluminum fluoride treated animals⁴³.

Guan *et al.*,²¹ reported pathological changes including decreased in the number of purkinje cells, demyelination, thickening and disappearance of dendrites in the brain of fluoride exposed rats. Quercetin administration reduces histopathological congestion, edema, neutrophil infiltration and structural disruption in spinal cord injury⁹. Chan-Min *et al.*,⁷ studied the morphological alterations of liver including leukocyte infiltration and extensive hepatocellular necrosis ameliorated by

quercetin treated animals. According to Kandaswamy *et al.*,⁴⁴ normal polygonal cells around the portal canal and sinusoid showed a layer of fenestrated endothelial cells. Kupffer cells are normal and few macrophages in the periportal zones and no apoptosis seen in liver treated with quercetin. Thus, these results indicate that quercetin could be an effective approach for attenuating the neurotoxicity *via* modulation of histological alteration induced by NaF.

CONCLUSION: NaF induced oxidative stress, behavioral and histological alterations in rat brain were significantly attenuated with quercetin treatment. Fluoride increases the production of free radicals which acts through oxidation of membrane lipids. Due to the destruction of membrane, neural cells get damage in terms of number, size and shape, thus leads to neurodegeneration which ultimately alter the behavior of rats. Quercetin prevents the excess generation of free radicals or eliminates the excess free radicals. Hence, it maintains normal neural cell membrane and oxidative status. Thus it can protect from fluoride induced neurodegeneration.

ACKNOWLEDGEMENT: Authors acknowledge the partial funding under UGC-BSR award (19-118/2014) and DSA-SAP-II and DST-FIST of Department of Zoology, OU.

CONFLICT OF INTEREST: We declare that we have no conflict of interest.

REFERENCES:

1. Yousef MI, Omar SA, El-Guendi MI and Abdelmegid LA: Potential protective effects of quercetin and curcumin on paracetamol- induced histological changes, oxidative stress, impaired liver and kidney functions and hepatotoxicity in rat. *Food Chemistry and Toxicology* 2010; 48: 3246-61.
2. Nabavi SF, Eslami S, Moghaddam AH, Naser J, Nabavi SM and Mohammad AE: Protective effects of quercetin against sodium fluoride-induced oxidative stress in rat erythrocytes. *Toxicology and Environmental Chemistry* 2011; 93(8): 1666-75.
3. Goncalves VSS, Rodriguez-Rojo S, De Paz E, Mato C, Martin A and Cocero MJ: Production of water soluble quercetin formulations by pressurized ethyl acetate-in-water emulsion technique using natural origin surfactants. *Food Hydrocolloids* 2015; 51: 295-304.
4. Ganiyu O, Ademosun AO and Ogunsuyi OB: Quercetin and Its Role in Chronic Diseases. *Drug Discovery from Mother Nature* 2016; 929: 377-87.
5. Nabavi SM, Nabavi SF, Eslami S and Moghaddam AH: *In vivo* protective effects of quercetin against sodium

- fluoride-induced oxidative stress in the hepatic tissue. Food Chemistry 2012; 132: 931-35.
6. Federico D: Life or death: neuroprotective and anticancer effects of quercetin. Journal of Ethnopharmacology 2012; 143: 383-96.
 7. Chan-Min L, Jie-Qiong M, Wan-Ru X, Si-Si L, Zhao-Jun F, Gui-Hong Z and Ai-Min W: Quercetin protects mouse liver against nickel-induced DNA methylation and inflammation associated with the Nrf2 / HO-1 and p38 / STAT1 / NF- κ B pathway. Food and Chemical Toxicology 2015; 82: 19-26.
 8. Omar AA: Molecular and biochemical investigations on the effect of quercetin on oxidative stress induced by cisplatin in rat kidney. Saudi Journal of Biological Science 2015; 22: 227-31.
 9. Jiang W, Huang Y, Han N, He F, Li M, Bian Z, Liu J, Sun T and Zhu L: Quercetin suppresses NLRP3 inflammation activation and attenuates histopathology in a rat model of spinal cord injury. Spinal Cord 2016; 54: 592-96.
 10. Nageshwar M, Sudhakar K, Reddy NCS and Reddy KP: Neuroprotective effects of curcumin on sodium fluoride induced behavioural and enzymatic changes in brain and muscles of rat. Journal of Environmental Biology 2017; 38: 675-81.
 11. Valdez-Jimenez L, Soria Fregozo C, Miranda Beltran ML, Gutierrez CO and Perez Vega MI: Effects of the fluoride on the central nervous system. Neuro. 2011; 26(5): 297-300.
 12. Madhusudhan N and Mahaboob BP: Effect of Maternal Exposure of Fluoride on Biometals and Oxidative Stress Parameters in Developing CNS of Rat. Biological Trace Element Research 2010; 133: 71-82.
 13. Seyed FN, Seyed MN, Solomon H, Akbar HM, Antoni S, Mahtab J and Ali Mohammad L: Hepatoprotective effect of gallic acid isolated from *Peltiphyllum peltatum* against sodium fluoride-induced oxidative stress. Industrial Crops and Products 2013; 44: 50-55.
 14. Ekambaram P, Vanaja P, Vimal G and Lakshmikanthan P: A brief review on experimental fluorosis. Toxicology Letters 2013; 223: 236-51.
 15. Harm HK and Steven B: Heat shock proteins as potential targets for protective strategies in neurodegeneration. The Lancet Neurology 2016; 15(7): 748-59.
 16. Mohammad JE, Zahra M, Homa R, Fatemeh S, Vahid P, Hadi A, Mahyar J and Mehdi M: Impaired Memory and Evidence of Histopathology in CA1 Pyramidal Neurons through Injection of A β 1-42 Peptides into the Frontal Cortices of Rat. Basic and clinical neuroscience 2016; 7(1): 31-41.
 17. Russell LB: Aluminum Induced Immunoexcito-toxicity in Neuro-developmental and Neurodegenerative Disorders. Current Inorganic Chemistry 2012; 2: 000-000.
 18. Chuan-Zhi G, Long-Yan R, Jin-Ping L and Guan ZZ: Changes of learning and memory ability and brain nicotinic receptors of rat offspring with coal burning fluorosis. Neurotoxicology and Teratology 2010; 32(5): 536-41.
 19. Zhang X and Shen X: Effect of fluoride exposure on synaptic structure of brain areas related to learning-memory in mice. Fluoride 2008; 41(2): 139-43.
 20. Varner JA, Jensen KF, Horvath W and Issacon RL: Chronic administration of aluminium fluoride or sodium fluoride to rats in drinking water: alterations in neuronal and cerebrovascular integrity. Brain Research 1998; 784: 284-98.
 21. Guan Z, Wang Y, Xiao K, Dai D, Chen Y and Liu J: Influence of chronic fluorosis on membrane lipids in rat brain. Neurotoxicology and Teratology 1998; 20: 537-42.
 22. Nageshwar M, Kirankumar N, Rajkiran RB, Chandrashakar RN and Pratap RK: Quercetin treatment against NaF induced oxidative stress related neuronal and learning changes in developing rats. Journal of King Saud University-Science 2017; 29: 221-29.
 23. Garcia YJ, Rodriguez-Malaver AJ and Penaloza N: Lipid peroxidation measurement by thiobarbituric acid assay in rat cerebellar slices. Journal of Neuroscience Methods 2005; 144(1): 127-35.
 24. Marklund S and Marklund G: Involvement of the superoxide anion radical in the autoxidation of pyrogallol and a convenient assay for superoxide dismutase. European Journal of Biochemistry 1974; 47(3): 469-74.
 25. Aebi H: Catalase *in vitro*. Methods in Enzymology 1984; 105: 121-26.
 26. Ellman GL: Tissue sulphhydryl group. Archives of Biochemistry and Biophysics 1959; 82: 70-77.
 27. Morris R: Developments of a water-maze procedure for studying spatial learning in the rat. Journal of Neuroscience Methods 1984; 11(1): 47-60.
 28. Gunn A, Bobeck EN, Weber C and Morgan MM: The influence of nonnociceptive factors on hot-plate latency in rats. Journal of Pain 2011; 12(2): 222-7.
 29. Leeson CR, Leeson TS and Paparo AA: Text Book of Histology, Fifth Edition, WB Saunders Company 1985.
 30. Romhanyi G: Selective differentiation between amyloid and connective tissue structures based on the collagen specific topo-optical staining reaction with Congo red. Virchows Archiv 1971; 354: 209-22.
 31. Shahid AS, Faiz UA, Mehtab K, Muhammad NA, Shafiq UR, Tae HK, Min WK and Myeong OK: Anthocyanins abrogate glutamate-induced AMPK activation, oxidative stress, neuro-inflammation, and neuro-degeneration in postnatal rat brain. Journal of Neuro-inflammation 2016; 286(13): 1-16.
 32. Swapnila C, Abhishek Y, Pramod K, Ramesh KK and Swaran JSF: Silymarin and quercetin abrogates fluoride induced oxidative stress and toxic effects in rats. Molecular and Cellular Toxicology 2011; 7: 25-32.
 33. David SS, Michael D, David PB, Greg LH, Chiharu H, Andrew BJ, Elizabeth D, Getzoff S, Craig C and John AT: Superoxide Dismutase Structures, Stability, Mechanism and Insights into the Human Disease Amyotrophic Lateral Sclerosis from Eukaryotic Thermophile *Alvinella pompejana*. Journal of Molecular Biology 2009; 385(5): 1534-55.
 34. Reham Z, Hamza NS, El-Shenawy, Hayat AA and Ismail: Protective effects of blackberry and quercetin on sodium fluoride-induced oxidative stress and histological changes in the hepatic, renal, testis and brain tissue of male rat. Journal of Basic Clinical Physiology and Pharmacology 2015; 26(3): 237-51.
 35. Sudhakar K, Nageshwar M and Reddy KP: Seed extract of *Abelmoschus moschatus* medik reverses NaF-induced behavioral changes through neurodegeneration and oxidative stress in brain of rat. Asian Journal of Pharmaceutical and Clinical Research 2017; 10(10): 1-7.
 36. Sajad H, Zaffar K, Shah Nawaz H, MIR MA, Athar H, Irfan J and Fayiza Y: Histopathological effects of varied fluoride concentration on Cerebrum in Albino Rats. Journal of Interdisciplinary Histopathology 2012; 1(1): 30-34.
 37. Sudhanshu S, Anjali S and Pankaj G: Effect of fluoride exposure on the intelligence of school children in Madhya Pradesh, India. Journal of Neurosciences in Rural Practice 2012; 3(2): 144-49.
 38. Aravind A, Dhanya RS, Ajay N, George S, Adarsh VJ and Kiran M: Effect of fluoridated water on intelligence in 10-12-year-old school children. Journal of International

- Society of Preventive and Community Dentistry 2016; 6(3): 237-42.
39. Tatsuo Y, Rika M and Toshihiko Y: Intracerebro-ventricular administration of 26RFa produces an analgesic effect in the rat formalin test. *Peptides* 2009; 30: 1683-88.
40. Masoud S, Mostafa RT and Mahmoud S: Clearance of Amyloid Beta Plaques from Brain of Alzheimeric Rats by *Lavandula angustifolia*. *Neuroscience and Medicine* 2012; 3: 362-67.
41. Wenjing Z, Jing Z and Zigui Z: Effects of Fluoride on Synaptic Membrane Fluidity and PSD-95 Expression Level in Rat Hippocampus. *Biological Trace Element Research* 2011; 139: 197-03.
42. Rodriguez JJ, Noristani HN, Hilditch T, Olabarria M, Yeh CY, Witton J and Verkhatsky A: Increased densities of resting and activated microglia in the dentate gyrus follow senile plaque formation in the CA1 subfield of the hippocampus in the triple transgenic model of Alzheimer's disease. *Neuroscience Letters* 2013; 552: 129-34.
43. Ranpariya VL, Parmar SK, Sheth NR and Chandrashekhar VM: Neuroprotective activity of *Matricaria recutita* against fluoride-induced stress in rats. *Pharmaceutical Biology* 2011; 49(7): 696-01.
44. Kandaswamy S, Senthamilselvan B, Sekaran S, Firdous A, Gunasekaran K and Jagadeesan A: Effect of Quercetin on Haematobiochemical and Histological Changes in the Liver of Polychlorinated Biphenyls-Induced Adult Male Wistar Rats. *Journal of Biomarkers* 2013; 960125: 1-12.

How to cite this article:

Nageshwar M, Sudhakar K and Reddy KP: Quercetin ameliorates oxidative stress, neural damage of brain and behavioral impairment of rat with fluoride exposure. *Int J Pharm Sci Res* 2018; 9(8): 3247-56. doi: 10.13040/IJPSR.0975-8232.9(8).3247-56.

All © 2013 are reserved by International Journal of Pharmaceutical Sciences and Research. This Journal licensed under a Creative Commons Attribution-NonCommercial-ShareAlike 3.0 Unported License.

This article can be downloaded to **ANDROID OS** based mobile. Scan QR Code using Code/Bar Scanner from your mobile. (Scanners are available on Google Playstore)